

# Biological welding – novel technique in the treatment of esophageal metaplasia

Volodymyr V. Tyselskyi<sup>1</sup>, Vitaliy Y. Poylin<sup>2</sup>, Andrey B. Kebkalo<sup>1</sup>

<sup>1</sup>Department of Surgery and Proctology, Gastrointestinal Surgery, Shupyk National Medical Academy of Postgraduate Education, Kyiv, Ukraine

<sup>2</sup>Feinberg School of Medicine, Gastrointestinal Surgery, Northwestern Medical Group, Chicago, United States

Article history: Received: 18.02.2020 Accepted: 18.04.2020 Published: 19.04.2020

## ABSTRACT:

**Introduction:** Biological welding – controlled action of high frequency current on living tissues, which leads to their structural changes and weld formation – connection with unique biological properties (strength, high elasticity, insensitivity to microbial infection, stimulating effect on the regeneration process, speed and quality which surpasses the normal uncomplicated healing) [22]. This method is used in various fields of surgery, but at the moment there is no data on its use in case of esophageal cylindrical (intestinal) metaplasia (further esophageal metaplasia or Barrett's esophagus).

**Objective:** The goal of this study is to evaluate biologic welding as a treatment option for patients with Barrett's esophagus.

**Materials and methods:** Single-center retrospective review of patients with short-segment Barrett's esophagus and metaplasia were treated by argon plasma coagulation (APC) or Paton's welding. This was followed by Nissen fundoplication. Primary outcome of this study was mucosal healing with morphological confirmation of the absence of metaplasia. The groups included patients with a short segment of the esophagus Barrett's C2-3M3-4 (Prague Classification 2004) and high dysplasia without nodule formation in combination with hiatal hernia (VI World Congress of the International Society for Esophageal Diseases; ISED) [23–25]).

**Results:** A total of 49 patients were included in the study with 25 patients treated by APC laser and 24 by biowelding. Four patients (16.0%) in the APC group developed stenosis and 5 patients (20.0%) developed recurrence compared to none in the biowelding group. Patients in the biowelding group had a significantly faster rate of mucosal healing leading to faster progression to Nissen fundoplication (at average 53 days) compared to APC laser group (surgery at 115 days).

**Conclusions:** Biological welding of Paton's is a safe and effective treatment option for patients with esophageal metaplasia.

## KEYWORDS:

esophagus metaplasia, destruction of the mucous Paton's biological welding, laparoscopic fundoplication

## ABBREVIATIONS

**APC** – Argon plasma coagulation

**GERD** – Gastroesophageal reflux disease

**HFW** – High-frequency welding

**ISED** – International Society for Esophageal Diseases

**RFA** – Radiofrequency Ablation

## INTRODUCTION

Esophageal metaplasia is a common precursor of adenocarcinoma and should be treated aggressively. The prevalence of esophageal metaplasia in Europe ranges from 2% to 5% [1]. The risk of developing glandular cancer in patients with cylindrical (intestinal) metaplasia is 0.5–0.8% per year or lifetime risk of 5–8% [2–4]. Gastroesophageal reflux disease (GERD) in combination with hiatal hernia is a common cause of this condition, diagnosed in 10–15% of patients with esophageal metaplasia [5, 6]. Because of that, endoscopic treatment of metaplasia is usually combined with surgery, such as Nissen fundoplication to minimize further damage (good results in terms of stopping reflux esophagitis [7, 8]).

There are multiple options for endoscopic treatment of esophageal metaplasia including APC, Radiofrequency Ablation (RFA), monopolar coagulation, cryodestruction, or photodynamic therapy. None of the methods has 100% success rate [9–11] and combined with patchy availability, need for specific training and

high cost of some of the equipment can significantly limit patient access to these potentially lifesaving procedures. In addition, a number of complications have been reported with all of the above techniques [12–15] related to damage associated with destruction of the mucosa.

High-frequency welding (HFW) is a new technique relying on lower temperature adjacent to the electrode to allow treatment of the superficial layers without significant deep tissue damage [16].

It has been successfully used for endoscopic hemostasis in gastrointestinal bleeding [16]. The goal of this study is to evaluate safety and outcomes of using HFW in combination with Nissen fundoplication in the treatment of patients with esophageal metaplasia and hiatal hernia.

## MATERIALS AND METHODS

This is a single-center retrospective review conducted at a tertiary care center between February 2017 and August 2019. Patients with esophageal metaplasia were treated with either APC laser during the initial part of the study between February 2017 and December 2017 or HFW during the later part (January 2018 and August 2019). All patients participating in the study had associated hiatal hernia and were treated with a course of proton pump inhibitors and underwent laparoscopic Nissen fundoplication after endoscopic treatment. All patients underwent EGD prior to the procedure and had histologically

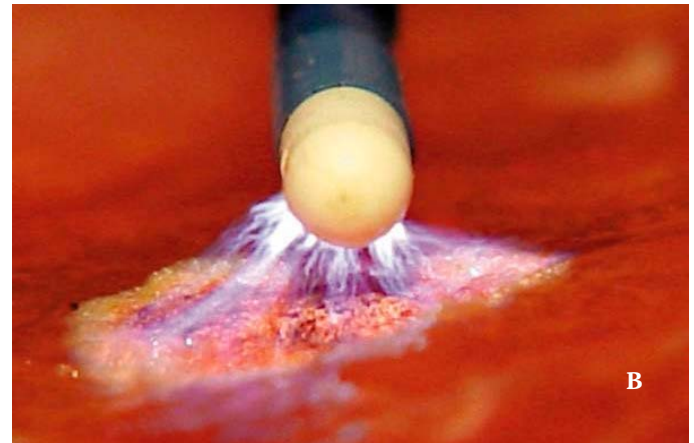
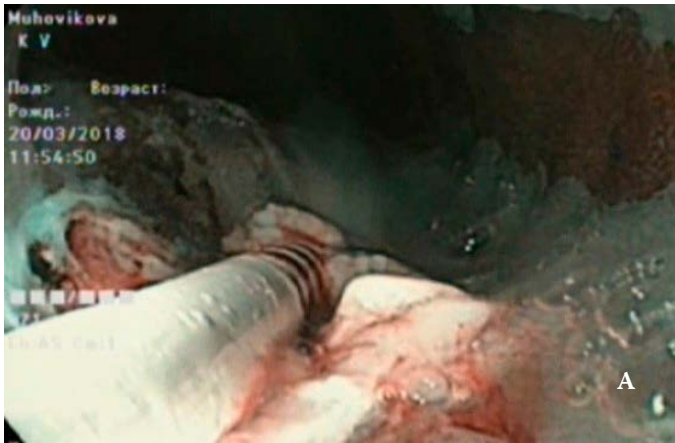
Fig. 1a. i 1b. Endoscopic treatment of dysplasia with HFW (A) and APC (B).

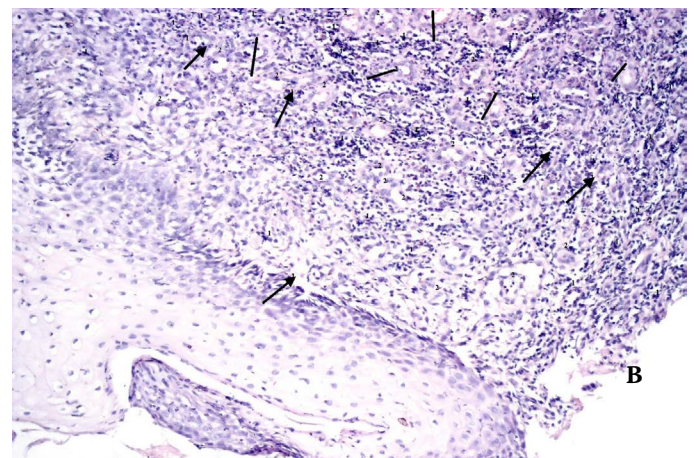
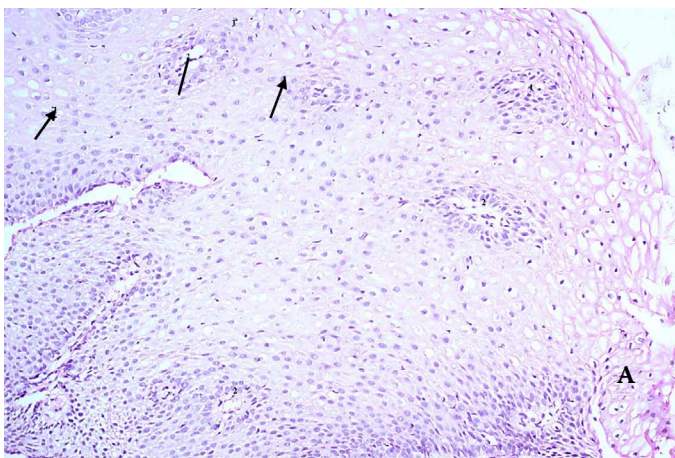


Fig. 2a. i 2b. Histological slides H&E staining after endoscopic treatment (A) 25 days after HFW showing complete absence of epithelial metaplasia with minimal leukocyte infiltration (1→) in the underlying tissues and scant angiogenesis (2→); (B) 25 days after APC showing the absence of metaplasia, but very pronounced leukocyte infiltration and angiogenesis and coarse granulation tissue.

confirmed metaplasia. Intraesophageal pH testing was performed on all patients (DeMeester index was more than 130) [17]. Patients with concurrent infections, carcinoma in situ, dysplasia without hiatal hernia, pregnancy and younger than 18 were excluded.

All patients received 40 mg of esomeprazole and 10 mg of motilium 12 hours prior to the procedure in order to reduce reflux into the esophagus. All endoscopic interventions were performed with monitored intravenous sedation.

High-frequency welding was performed with Paton's mucous membrane biological welding (EKVZ-300).

Patonmed EKVZ-300 device (E. O. Paton Electric Welding Institute of the National Academy of Sciences of Ukraine, Kiev, Ukraine) [16] in automatic welding mode with electrical resistance is set at 20 Ohm. A flexible bipolar endoscopic probe with a diameter of 8.5 Fr at the end of which two electrodes are twisted in a spiral (the length of open electrodes is 5 mm) is connected to this device. The "automatic welding" mode independently determines the optimal time that is necessary to achieve complete destruction. As current passes through the electrode, the temperature of the tissue rises until it reaches the temperature of protein coagulation and denaturation (600°C). At that point resistance in the dehydrated tissue rises dramatically, which leads to feedback loop for the machine to stop welding (Fig. 1a.).

APC laser treatment was performed with Bowa arc plus 200; monopolar cable, endoscopy, 2.8 mm socket, for 4 mm, 4.5 m; program 11: ArcPlus Online (Fig. 1b.).

All patients were discharged from hospital a day after the procedure on 20 mg esomeprazole twice a day and motilium 10 mg 3 times a day for 14 days. All patients underwent EGD at 1, 3 and 6 months after the procedure with biopsies taken for histological evaluation [18], At that point decision was made on timing of Nissen fundoplication based on patient recovery and degree of inflammation.

Statistical analysis was performed with STATISTICA 10 for Windows. To classify the data, the Shapiro-Wilk test was used (the number of studied patients <50), and since the data sets did not have a normal distribution law ( $P < 0.05$ ), the nonparametric Mann-Whitney U-test was used to compare the quantitative studied parameters. To confirm the significance of differences in the observed parameters, a significance level of  $P = 0.05$  was used. To assess quality indicators,  $\chi^2$  criterion was applied at the same significance level.

This study was approved by the ethics committee of the Shupyk National Medical Academy of Postgraduate Education. Discussion was held with patients qualified for the study about novelty of the technique and standard alternative (APC).

## RESULTS

A total of 49 patients were included in this study, 25 in the APC arm and 24 in the HFW arm. There were no differences in demographic characteristics or comorbidities (Tab. I.). There were 4 patients (16.0%) in the APC group that developed stenosis compared to none in the HFW group ( $P = 0.041$ ). Five patients (20.0%) in the APC group developed recurrence requiring further treatment compared to none in the HFW group ( $P = 0.021$ ). Four patients in the APC group (16.0%) and none in the HFW group reported significant pain in the epigastric region after the procedure (Tab. II.).

All patients presented for all the follow-up studies.

Endoscopic evaluation of the treated area revealed significantly less peel, damage, and necrosis in the HFW group when compared to the APC group (Fig. 2a.–b.). This was histologically confirmed by comparing immediate biopsies showing no more than 1-mm deep necrosis in the HFW group (Fig. 2a.–b.). Subsequent EGD and biopsies showed a significantly shorter time to histological remission in the HFW group when compared to the APC group  $53 \pm 7$  vs  $115 \pm 4$  ( $P < 0.05$ ).

In turn, the second stage of treatment was performed in the first group after  $120 \pm 7$  days, and in the second group after  $60 \pm 7$  days from the time of intervention.

All patients underwent Nissen fundoplication although the procedure was delayed in the APC group because of inflammation noted on EGD indicative of longer mucosal healing. There were no surgical complications in either group (Tab. II.).

## DISCUSSION

We present the first study looking at the novel technique – High-Frequency Welding in the treatment of esophageal metaplasia. HFW is a safe and effective technique in the treatment of this disease. This study shows significant benefit in using this technique when compared to standard APC treatment in producing better and faster tissue healing and repair as well as much lower risk of complications. Both morphological and histological examination revealed no deep tissue damage and very quick and non-painful recovery. Combined with absence of significant complications such as stenosis and recurrence, HFW is a good option for patients with metaplasia. The proposed mechanism for this technique utilizing negative feedback loop with sufficiently dehydrated tissue and welding automatically stops avoiding further damage. Lower temperature needed to achieve the desired results and nearly smokeless environment make it easier to adopt (because of the feedback loop no significant additional training is needed to figure out the duration of treatment). Tissue damage recovery is quicker, allowing for quicker progression to anti-reflux surgery, which can make it easier for patients living in the area with difficult access to care and when traveling may be an issue. Relatively low cost of the equipment and supplies can result in much wider use and improve patients' access to cancer-preventing procedure.

**Tab. I.** Patient demographics and comorbidities.

	APC (25 PATIENTS)	HFW (24 PATIENTS)
Age, years	45.1 $\pm$ 7.2	47.3 $\pm$ 6.2
Gender (% Male)	17 (68)	15 (62.5)
BMI	28.6 $\pm$ 4.1	26.6 $\pm$ 5.6
Diabetes mellitus type 2	1 (4 %)	2 (8.33%)
Coagulopathy	1 (4 %)	1 (4.16%)
Autoimmune connective tissue disease	1 (4 %)	0 (0%)

**Tab. II.** Clinical and pathological outcomes after endoscopic and surgical treatment.

COMPLICATIONS AFTER STAGE 1	APC (N = 25)		HFW (N = 24)		P
	N	%	N	%	
Stenosis	4	16.0	0	0	0.041*
Relapse (presence of islets of residual tissue)	5	20.0	0	0	0.021*
Pain	4	16.0	0	0	0.041*
COMPLICATIONS AFTER STAGE 2					
Dysphagia resolved after surgery alone	8	32.0	2	8.33	0.040*
Dysphagia requiring additional medications	6	24.0	1	4.16	0.048*
Stricture of the esophagus eliminated by balloon dilatation	4	16.0	0	0	0.041*

A number of other techniques exist for the treatment of Barrett's esophagus, with RFA being one of the more commonly used techniques. Studies show (Cochrane working group and Orman meta-analysis of 3802 cases) that eradication in the presence of dysplasia occurs in 86–91%, and the frequency of esophageal strictures reaches 5–8% [19–21]). However, RFA is not currently available in our region, so only a comparison to APC could be made for the purposes of this study. Our results in the APC group are consistent with previously published results showing complete eradication rates between 36 and 100% and relapse rates of up to 66%, and recommendation by American Association of Gastroenterologists Practice Review of Barrett's Esophagus [12].

Main drawbacks of this study include retrospective non-randomized nature and small number of patients. Although consecutive patients were included in the study, the possibility of bias is still present in selecting what procedure was performed especially during the transition period. Although only patients with higher-grade Barrett's esophagus were included, and detailed documentation on the extent of the disease was not available for a number of patients, that created an additional bias. Only short- and intermediate-term results are available.

## CONCLUSIONS

High-frequency welding is a safe and effective low-cost technique for the treatment of esophageal metaplasia. Further studies are needed to examine longer-term results of this technique as well as to compare it to other treatment modalities for Barrett's esophagus.

## REFERENCES

- Isakov V.A.: NERB and ERD: two sides of the same coin. *Clinich. gastroenterol. and hepatol. Russian edition*, 2008; 1, 3: 166–168.
- Provenzale D., Kemp J.A., Arora S., Wong J.B.: A guide for surveillance of patients with Barrett's esophagus. *Amer. J. Gastroenterol.*, 1994; 89, 670–680.
- Cook M.B., Coburn S.B., Lam J.R., Taylor P.R., Schneider J.L. et al.: Cancer incidence and mortality risks in a large US Barrett's oesophagus cohort. *Gut*, 2018; 67(3): 418–529.
- Coleman H.G., Xie S.H., Lagergren J.: The Epidemiology of Esophageal Adenocarcinoma. *Gastroenterology*, 2018; 154(2): 390–405.
- Mazurenko O.: Gastroesophageal reflux disease: where we are now and what we are striving for. *Health of Ukraine*, 2009; 6(1): 18–19.
- Weusten B., Bisschops R., Coron E., Dinis-Ribeiro M., Dumonceau J.M. et al.: Endoscopic management of Barrett's esophagus: European Society of Gastrointestinal Endoscopy (ESGE) Position Statement. *Endoscopy*, 2017; 49(2): 191–198.
- Stefanidis D., Hope W.W., Kohn G.P., Reardon P.R. et al.: Guidelines for surgical treatment of gastroesophageal reflux disease. *Surgical endoscopy*, 2010; 24(11): 2647–2669.
- Shan C.-X., Zhang W., Zheng X.-M., Jiang D.-Z. et al.: Evidence-based appraisal in laparoscopic Nissen and Toupet funduplications for gastroesophageal reflux disease. *World journal of gastroenterology*, 2010; 16(24): 3063–3071.
- Rees J.R., Lao-Sirries P., Wong A., Fitzgerald R.C.: Treatment for Barrett's oesophagus. *Cochrane database of systematic reviews.*, 2010; 1: CD004060.
- Sie C., Bright T., Schoeman M., Game P. et al.: Argon plasma coagulation ablation versus endoscopic surveillance of Barrett's oesophagus: late outcomes from two randomized trials. *Endoscopy*, 2013; 45(11): 859–865.
- Nelsen E.M., Hawes R.H., Iyer P.G.: Diagnosis and management of Barrett's esophagus. *Surgical clinics of North America*, 2012; 92(5): 1135–1154.
- Spechler S.J., Sharma P., Souza R.F., Inadomi J.M.: American Gastroenterological Association technical review on the management of Barrett's esophagus. *Gastroenterology*, 2011; 140(3): e18–e13.
- Shaheen N.J., Overholt B.F., Sampliner R.E., Wolfsen H.C.: Durability of radiofrequency ablation in Barrett's esophagus with dysplasia/ *Gastroenterology*, 2011; 141(2): 460–468.
- Wani S., Puli S.R., Shaheen N.J., Westhoff B. et al.: Esophageal adenocarcinoma in Barrett's esophagus after endoscopic ablative therapy: a meta-analysis and systematic review. *The American journal of gastroenterology*, 2009; 104(2): 502–513.
- Grubnik V., Malinovsky A.: Critical aspects of laparoscopic surgery of gastroesophageal reflux disease and hernia of the esophageal hole of the diaphragm. *VMV-typography*, 2015.
- Tryliskyy Y., Kebkalo A., Wong Ch.S., Rublenko S., Rublenko M. et al.: Safety analysis of endoscopic haemostasis using a high-frequency live tissue electric welding device – EKVZ300 PATONMED. *Gastroenterology Rev*, 2018; 13(3): 234–237, DOI: <https://doi.org/10.5114/pg.2018.78289>
- Barkalova E.V., Hovsepian M.A., Andreev D.N. et al.: Evaluation of high-resolution esophagus pH-impedometry and manometry indicators in patients with various forms of gastroesophageal reflux disease and Barrett's esophagus. *Farmateka*, 2017; 20: 50–56.
- Craig C.R., Nicholas J.S.: Management of Barrett esophagus following radiofrequency ablation. *Gastroenterology & Hepatology*, 2019; 15(7).
- Orman E.S., Li N., Shaheen N.J.: Efficacy and durability of radiofrequency ablation for Barrett's Esophagus: systematic review and meta-analysis. *Clinical gastroenterology and hepatology*, 2013; 11(10): 1245–1255.
- Shaheen N.J., Overholt B.F., Sampliner R.E., Wolfsen H.C.: Durability of radiofrequency ablation in Barrett's esophagus with dysplasia. *Gastroenterology*, 2011; 141(2): 460–468.
- Rees J.R., Lao-Sirrieix P., Wong A., Fitzgerald R.C.: Treatment for Barrett's oesophagus. *Cochrane database of systematic reviews*, 2010; 1: CD004060.
- Paton E.O.: Electric Welding Institute of the NAS of Ukraine, 03680, Kyiv, Ukraine. Department for Welding and Related Technologies for Medicine and Environment, 2019. <http://patonmed.com.ua/en/home>
- Stein H.J. and panel of experts: Esophageal cancer: Screening and surveillance. *Dis. Esoph.*, 1996; 9(suppl. 1): 319.
- Zaratyants O.V., Maev I.V., Smolyannikova V.A., Movtaeva P.R.: Pathological anatomy of Barrett's esophagus. *Archive of pathology*, 2011; 3: 21–26.
- Melchenko D.S., Belova V.G.: Barrett's esophagus: clinical and morphological comparisons. *Honey. Visualization*, 2006; 5: 74–82.

Liczba słów: 2460

Liczba stron: 5

Tabele: 2

Ryciny: 2

Piśmiennictwo: 25

DOI: 10.5604/01.3001.0014.1176

Table of content: <https://ppch.pl/resources/html/articlesList?issuelid=0>

Copyright: Copyright © 2020 Fundacja Polski Przegląd Chirurgiczny. Published by Index Copernicus Sp. z o. o. All rights reserved.

Competing interests: The authors declare that they have no competing interests.



The content of the journal „Polish Journal of Surgery” is circulated on the basis of the Open Access which means free and limitless access to scientific data.

This material is available under the Creative Commons – Attribution 4.0 GB. The full terms of this license are available on: <http://creativecommons.org/licenses/by-nc-sa/4.0/legalcode>Corresponding author: Volodymyr V. Tyselskyi; Department of Surgery and Proctology, Gastrointestinal Surgery, Shupyk National Medical Academy of Postgraduate Education, Kyiv, Ukraine; 9 Dorohozhytska Str., Kyiv, 04-112 Ukraine; Phone: +38 (044) 205-49-46, +38 (044) 205-48-27, +38 (044) 205-48-69; E-mail: [Vovik-tc@ukr.net](mailto:Vovik-tc@ukr.net)Cite this article as: Tyselskyi V.V., Poylin V.Y., Kebkalo A.B.: Biological welding – novel technique in the treatment of esophageal metaplasia; *Pol Przegl Chir* 2019; 91: 1–5; DOI: 10.5604/01.3001.0014.1176 (Advanced online publication)

