

# Efficacy of surgical treatment in patients with post-traumatic facial nerve palsy

**Authors' Contribution:**

A – Study Design  
B – Data Collection  
C – Statistical Analysis  
D – Data Interpretation  
E – Manuscript Preparation  
F – Literature Search  
G – Funds Collection

Joanna Marszał<sup>BDEF</sup>, Anna Bartochowska<sup>ADEF</sup>, Wojciech Gawęcki<sup>BDE</sup>, Małgorzata Wierzbicka<sup>AD</sup>

Department of Otolaryngology and Laryngological Oncology, Medical University of Poznan, Poland;  
Head: prof. Małgorzata Wierzbicka MD PhD

Article history: Received: 15.01.2021 Accepted: 12.02.2021 Published: 16.02.2021

**ABSTRACT:**

**Introduction:** The most common mechanism of post-traumatic facial nerve palsy are road accidents and falls. Treatment schemes as well as proper timing of surgery are still controversial.

**Aim:** The aim of the study was the evaluation of the effects of surgical treatment in patients with post-traumatic facial nerve palsy. Treatment results were correlated with epidemiological factors, mechanism of injury, level of nerve damage, time of surgery and its extent.

**Material and methods:** 9 patients with facial nerve palsy after head trauma were analyzed. In all patients complete paresis of the VII nerve occurred immediately after the injury. In 5 patients the nerve was damaged in the course of the longitudinal fracture of the temporal bone, in 3 as a result of its transverse fracture while in one woman there was no evident fracture line. In all cases, surgical treatment was performed between 4 days and 13 weeks after the trauma. In all cases transmastoid approach was used. Edema lesions of the nerve dominated in 6 patients, in two cases a bone fragment was noted along its course, in one person nerve was disrupted but primary reconstruction was not possible – the man was excluded from further analysis. The results of treatment were assessed by House-Brackmann (HB) scale 12 months after the procedure.

**Results:** Very good (HB I) or good (HB II) recovery of facial nerve function was achieved in 2 and 4 out of 8 patients respectively. Surgical timing, the extent of surgery, patient's age, mechanism of injury and level of nerve damage had no effect on the final outcome.

**Conclusions:** The management of post-traumatic facial nerve palsy should be individual. The commonly accepted recommendation on surgical treatment is to undertake it in patients with immediate-onset and complete paralysis. Patients who, due to their severe general condition, cannot undergo early facial nerve decompression may benefit from delayed treatment for up to 3 months after the injury.

**KEYWORDS:**

craniofacial injury, facial nerve decompression, facial nerve palsy, temporal bone fracture

**ABBREVIATIONS**

**CT** – computed tomography  
**ENoG** – electroneurography  
**HB** – House-Brackmann scale  
**HRCT** – high resolution computed tomography  
**MRI** – magnetic resonance imaging

**INTRODUCTION**

Injuries are the third most prevalent cause of peripheral facial nerve palsy (after Bell's palsy and infections) [1]. According to the literature data, blunt head trauma can lead to damage of cranial nerve VII in approx. 1.5% of people affected by such trauma [2]. In fractures of the temporal bone pyramid, it is more common in patients with transverse (50%) than longitudinal (20–30%) fractures [3–5]. The statistics of post-traumatic causes of damage to cranial nerve VII are dominated by road traffic injuries and falls from height [1].

Facial nerve (7<sup>th</sup> cranial nerve) palsy leads to impairment of facial muscle function, which significantly affects the aesthetics of the

face, causing a visible asymmetry. The functional effects of damage also include the inability to completely close the palpebral fissure, which can lead to conjunctivitis or a corneal ulcer, problems with eating (and especially with drinking), salivation, difficulty in articulation and synkinesis. Many cases also involve disturbances in taste disorders and tear secretion. For almost all patients, facial nerve palsy significantly reduces the quality of life. This most visible cranial neuropathy has a negative impact on both the psychological and social aspects of life [6–8].

The facial nerve in the temporal bone traverses through the closely surrounding bony canal, which makes it susceptible to swelling and pressure [9]. Most of the injuries result in contusion, stretching, intraneural hematoma, fibrosis around a nerve or partial nerve crush, but continuity of the nerve is rarely interrupted [10]. This pathomechanism significantly contributes to the controversy of the treatment of post-traumatic facial paralysis. Many clinicians choose conservative treatment based on systemic steroid therapy. Some centers almost always choose the surgical variant, and the extent of surgery depends on the locations and mechanisms of injury. Most often it consists in an attempt to decompress the facial nerve by opening the bony canal and incising the

Tab. I. Group of patients with post-traumatic facial nerve palsy.

No	Sex	Age	Type of fracture	Schirmer`s test	Time from injury to surgery [weeks]	Intraoperative image	Extent of decompression/ other treatment	Other injury	HB score before treatment	HB score 12 months after treatment
1	M	34	longitudinal	tear film deficit	0.5	edematous changes	full decompression	damage to the eardrum and ossicles	VI	II
2	F	54	longitudinal	tear film deficit	10	edematous changes	decompression in tympanic segment	damage to the eardrum and ossicles	VI	II
3	F	20	longitudinal	tear film deficit	2	partial nerve crush, bone splinter in tympanic segment	bone fragment removal	damage to the eardrum and ossicles	VI	II
4	F	23	fracture fissure was not visualized	standard	10	edematous changes	decompression in tympanic segment	–	VI	I
5	F	47	transverse	standard	13	edematous changes	decompression in tympanic segment	–	VI	II
6	M	46	longitudinal	standard	1,5	partial nerve crush, bone splinter in tympanic segment	bone fragment removal	damage to the auditory ossicles	VI	I
7	M	65	transverse	standard	5	rupture of continuity of tympanic segment	management of liquorrhea, primary nerve reconstruction was not performed	–	VI	VI
8	M	40	longitudinal	tear film deficit	1	edematous changes	full decompression	damage to the eardrum and ossicles	VI	III
9	M	41	transverse	tear film deficit	4	edematous changes	full decompression	–	VI	IV

HB – House-Brackmann scale

capsule, or it is associated with the removal of bone fragments, which usually causes its segmental crushing [9, 11–12]. However, most authors emphasize that there is no universal strategy. When choosing a therapy, the results of physical examination and medical history, imaging studies and functional tests should be taken into account. They allow to assess the degree and type of paralysis (with sudden or delayed onset), as well as the site of nerve damage. Surgical treatment is widely accepted in the case of sudden onset of symptoms and complete paresis [13–14]. Most reports indicate significantly better results if surgical treatment is performed up to 4 weeks after the injury [10]. It is to be remembered, however, that due to cranio-cerebral injuries and accompanying grave general condition, many patients after road traffic accidents stay in intensive care units in a state of sedation. In such case, assessment of the specific time of onset of facial nerve palsy and its degree is difficult, and the possibility of surgical intervention is delayed. Nevertheless, it is emphasized that even delayed nerve decompression can bring measurable benefits in the majority of patients [15].

## AIM

The main aim of the study was to analyze the effects of surgical treatment in patients with post-traumatic intratemporal

facial nerve injury. Specific objectives concerned the assessment of the dependence of its results on epidemiological factors, the mechanism of injury, the site of nerve damage, the time and scope of treatment.

## MATERIAL AND METHODS

From January 2015 to December 2019, 9 patients with facial nerve palsy after cranio-cerebral trauma were hospitalized at the Department of Otolaryngology and Laryngological Oncology at Poznań University of Medical Sciences (Tab. I.). The analyzed group consisted of 4 women and 5 men aged 23 to 65 (mean age 41.1 years).

The most common cause of injury in the study group was traffic accident (4 patients). Three patients sustained a head injury in a state of intoxication and two after an unfortunate fall down the stairs. In all cases, the paralysis occurred immediately after injury, in 8 patients unilaterally, and in one woman bilaterally. All unilateral cases were found with complete paresis of the 7th nerve (grade VI on the House-Brackmann scale), while the patient with bilateral dysfunction suffered from complete paresis (grade VI) on the right side, and incomplete paralysis (grade IV) on the left side.

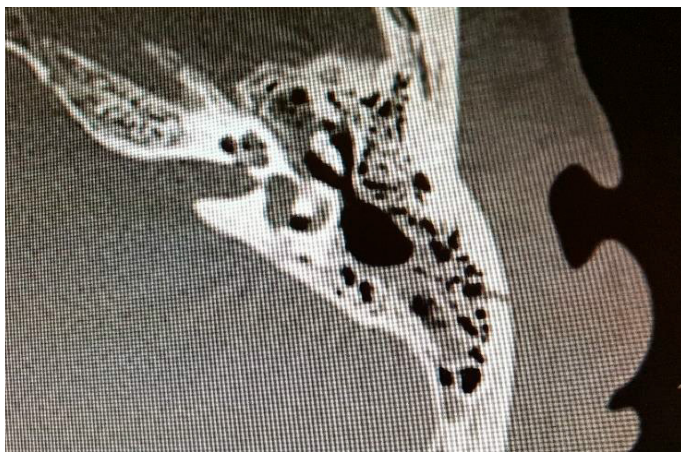

Fig. 1. HRCT scan of the temporal bone – longitudinal fracture of the left temporal bone.

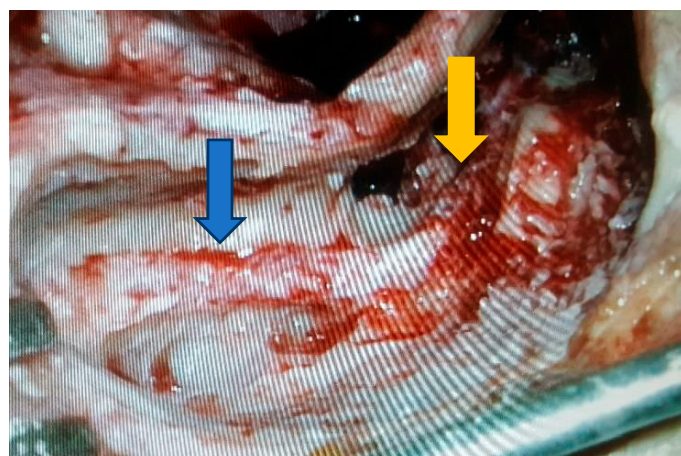


Fig. 2. Intraoperative image of the facial nerve decompressed in the mastoid (blue arrow) and tympanic (yellow arrow) segments; (left ear, antrumastoidectomy, posterior tympanotomy and epitympanotomy were performed, luxated incus and head of malleus were removed).

All patients underwent computed tomography of the head with contrast or magnetic resonance imaging (MRI) of the head, high resolution computed tomography (HRCT) of the temporal bones, and the Schirmer's test. In 5 patients, the HRCT image confirmed a longitudinal fracture of the temporal bone (Fig. 1.), and in 3 patients a transverse fracture was found. In one female patient, preoperative evaluation of the scans revealed no apparent fracture fissure in the petrous pyramid. There were no intracranial complications. The Schirmer's test revealed tear film deficiency in 5 cases.

All patients were treated surgically. The procedure was performed from 4 days to 13 weeks after the trauma. In all cases, intravenous steroid therapy was administered immediately after the accident. Timing of surgery was determined by the general condition of the patients. In the female patient without an evident fracture fissure in the HRCT of the temporal bones, it was decided to decompress the VII nerve due to complete palsy which lasted 10 weeks, despite the use of systemic steroid therapy during this period. In this case, the fracture fissure was also not visualized intraoperatively.

All patients were operated on via the transmastoid approach using a closed technique (with preservation of the posterior wall of the

external auditory canal, i.e., canal wall-up). Depending on the intraoperative image and the results of imaging and functional examinations, antrumastoidectomy was supplemented with a posterior tympanotomy, incus removal or extended epitympanotomy. Edematous changes of the nerve predominated in 6 patients, with no disruption of continuity of nerve or mechanical damage. In this group, 3 patients underwent complete decompression of the tympanic and mastoid segments, i.e., from the geniculate ganglion to the stylomastoid foramen (Fig. 2.). In 3 consecutive patients the area of decompression was smaller and depended on the site of visible edema or nerve injury. In 2 patients a bone fragment was visualized along the course of the VII nerve, which was removed. In one patient, continuity of the facial nerve in the tympanic segment was completely disrupted during the procedure, revealing the proximal and distal nerve stump. Unfortunately, due to severe liquorrhea along the fracture fissure and difficulties in managing it, it was not possible to reconstruct the nerve at the same time. The patient did not decide on the next stage of treatment, and was excluded from further analysis. Four patients had visible perforation of the tympanic membrane, and 5 patients had a rupture of the ossicular chain. Simultaneous tympanoplasty was not undertaken.

The result of the Schirmer's test was correlated with the intraoperative image indicating the site of nerve damage. It turned out that 3 cases of results were false positive.

The degree of facial nerve injury before and after treatment was assessed using the House-Brackmann scale. Complete recovery of the facial nerve function (to HB I) was considered a good treatment effect, while achieving HB II within 12 months after the surgery was recognized as satisfactory.

Due to the small size and strong diversification of the study group, we used descriptive statistics.

## RESULTS

Complete recovery of facial nerve function (HB I) was achieved in 2 patients, satisfactory recovery (HB II) in 4 consecutive ones. Two patients achieved an unsatisfactory result: in one patient, the function of nerve VII was assessed at HB III after 12 months, in another – at HB IV; the latter was a 41-year-old man with an alcohol abuse problem who did not undertake postoperative rehabilitation. One of the patients did not decide to reconstruct the fully interrupted VII nerve due to their family situation, so the palsy remained complete – the patient was excluded from further analyzes.

All cases of unsatisfactory recovery of nerve VII function were seen in men, while all surgeries in women were successful. The patient's age, the mechanism of injury and the site of nerve damage, as well as the extent of procedure, did not affect the final outcome. Similarly, the timing of treatment was irrelevant – even patients operated 10 or 13 weeks after the injury achieved a good (HB I) or satisfactory (HB II) result.

Treatment outcomes are shown in Tab. I.



## DISCUSSION

Polish and English literature provides no detailed or uniform recommendations regarding the treatment of patients with post-traumatic facial nerve injury. Surgical treatment still gives rise to many controversies, and the results reported in the literature vary widely [16]. Nash et al. conducted a systematic review of treatment effects in 612 patients with paralysis of the VII nerve after cranio-cerebral trauma. They found that only 23% of the operated patients achieved full recovery of the nerve function [17]. On the other hand, Hato et al. analyzed 66 patients who underwent decompression of the facial nerve due to post-traumatic paralysis. Complete recovery of nerve function was achieved in 47% of cases, satisfactory in another 23% patients [14]. In the analyzed group, the results were as follows: a good result (HB I) was obtained in 2 patients (25%), while a satisfactory result (HB II) in subsequent 4 (50%) patients.

Yedav et al. [1] and Xu et al. [10] analyzed the influence of patients' age and sex on the result of decompression of cranial nerve VII. The authors did not see any significant correlations. Although in our study group men achieved worse results, it seems that those results were mainly dependent on other factors – the type of fracture, the mechanism of nerve damage, and undertaking further rehabilitation.

It is generally acknowledged that decompression of the facial nerve is indicated in the case of VII cranial nerve impairment which occurs immediately after injury and in complete nerve palsy [13–14]. All patients in our study group fulfilled both conditions. Other qualification criteria for surgical treatment include abnormal results of electrophysiological tests [18]. The most commonly used techniques include electroneurography (ENoG) and electromyography (EMG). ENoG is used in the first days after the injury. Ulug and Ulubil emphasize its particular value in the first 6 days after the onset of paralysis. Damage to more than 90% of the motor fibers is an indication for surgical treatment [19]. On the other hand, EMG may be useful 2 weeks after paralysis. The result confirming the lack of nerve repair is an indication for surgical intervention [1, 20]. Unfortunately, electrophysiological tests were impossible in patients from our group. Qualification for surgical treatment, in addition to clinical examination and computed tomography (CT)/MRI of the head and HRCT of the temporal bones, also includes the Schirmer's functional test [21] – the damage located proximal to the greater petrosal nerve causes a deficit of the tear film. Abnormal results for this test were obtained in 5 cases. However, in 3/5 patients the intraoperative and clinical picture was inconsistent with the predicted level of damage. Our results do not differ from those presented by other authors who found a false positive result of the Schirmer's test in 54.5–74% of patients [1, 22].

A careful analysis of symptoms and imaging tests allows for proper planning of the operation and selection of the optimal surgical approach [23]. In pathologies associated with facial nerve palsy, transmastoid approach, middle cranial fossa approach or translabyrinthine approach is used. The recent development of endoscopic ear surgery has caused the emergence of more and more reports of endoscopic surgery [24]. When the damage to the facial nerve affects the tympanic or mastoid segments, transmastoid approach

remains the gold standard [1, 25]. Middle cranial fossa approach is a recognized solution in labyrinthine damage with simultaneous hearing preservation. That said, it is technically difficult and may cause complications such as brain edema, subdural hematoma, meningitis or liquorrhea. Labyrinthine approach makes it possible to visualize the facial nerve from the stylomastoid foramen to the brainstem. However, it is associated with postoperative hearing loss, therefore it is reserved for facial nerve palsy coexisting with deafness or profound hearing loss. Endoscopic access is a minimally invasive diagnostic tool used to visualize the geniculate ganglion. However, it requires rupture of ossicular chain continuity and does not allow for managing liquorrhea [26]. In our patients, we used microscopic transmastoid approach each time.

Another issue that remains unclear is the time (counted from the time of onset of facial nerve palsy) in which surgical intervention should be undertaken. Most reports indicate that early surgical treatment produces the best results [14–15, 27]. Xu et al. emphasize that the best results are delivered when decompression of the facial nerve is performed within one month of the onset of paralysis. However, the authors also point out that starting treatment within 3 months of the injury, when decompression cannot be performed earlier due to the patient's grave general condition, allows for complete or satisfactory restoration of nerve function in 67% of patients [10]. Hato et al. conducted an analysis of 66 patients, and observed worse results when the procedure was delayed for more than 2 months from the injury [14]. Similar conclusions were reached by Abbaszadeh-Kasbi et al. who also noticed significantly better results in decompression performed up to 2 months after the trauma [28]. The Italian team of Quaranta et al. obtained results at grades HB I and HB II in 78% of patients treated surgically between 27 and 90 days after traumatic injury to cranial nerve VII [15]. In our study group, after excluding the patient with complete disruption of facial nerve continuity, in whom primary reconstruction was not undertaken due to abundant liquorrhea, good (HB I) and satisfactory (HB II) results were obtained in 6/8 (75%) of patients. Worse results were not observed in patients operated on 10 or even 13 weeks after the injury.

## CONCLUSIONS

The management of post-traumatic facial nerve palsy should be determined on a case-by-case basis. Planning treatment requires consideration of many factors, including: the patient's general condition, results of imaging and functional tests, and the experience of a given center. The Schirmer's test results should be interpreted with caution due to the high false-positive rate. Surgical treatment is recommended in the case of impaired function of the facial nerve immediately after the trauma and in complete nerve paralysis. Transmastoid approach allows for decompression of the facial nerve in the mastoid and tympanic segments, including the geniculate ganglion. Patients who are in grave general condition and cannot undergo early decompression of cranial nerve VII may benefit from delayed treatment for up to 3 months after the injury.

## REFERENCES

1. Yadav S., Panda N.K., Verma R., Bakshi J., Modi M.: Surgery for post-traumatic paralysis: are we overdoing it? *Eur Arch Otorhinolaryngol*, 2018; 275(11): 2695–2703.
2. Devriese P.P.: *Facial Paralysis After Trauma of the Skull*. W: *Traumatology of the Skull Base*, Ed.: M. Samii, J. Brihaye, Springer, Berlin 1983.
3. Brodie H.A., Thompson T.C.: Management of complications from 820 temporal bone fractures. *Am J Otol.*, 1997; 18(2): 188–197.
4. Diaz R.C., Cervenka B., Brodie H.A.: Treatment of Temporal Bone Fractures. *J Neurol Surg B Skull Base*, 2016; 77(5): 419–429.
5. Prasetyo E., Oley M.C., Faruk M.: Split hypoglossal facial anastomosis for facial nerve palsy due to skull base fractures: A case report. *Ann Med Surg (Lond)*, 2020; 59: 5–9.
6. Vajpayee D., Mallick A., Mishra A.K.: Post Temporal Bone Fracture Facial Paralysis: Strategies in Decision Making and Analysis of Efficacy of Surgical Treatment. *Indian J Otolaryngol Head Neck Surg.*, 2018; 70(4): 566–571.
7. Matos Cruz A.J., De Jesus O.: Facial Nerve Repair. *StatPearls [Internet]*. Treasure Island (FL), 2021; PMID: 32809458, Bookshelf ID: NBK560623.
8. Owusu J.A., Stewart C.M., Boahene K.: Facial Nerve Paralysis. *Med Clin North Am.*, 2018; 102(6): 1135–1143.
9. Lee P.H., Liang C.C., Huang S.F., Liao H.T.: The Outcome Analysis of Traumatic Facial Nerve Palsy Treated With Systemic Steroid Therapy. *J Craniofac Surg.*, 2018; 29(7): 1842–1847.
10. Xu P., Jin A., Dai B., Li R., Li Y.: Surgical timing for facial paralysis after temporal bone trauma. *Am J Otolaryngol.*, 2017; 38(3): 269–271.
11. Sun D.Q., Andresen N.S., Gantz B.J.: Surgical Management of Acute Facial Palsy. *Otolaryngol Clin North Am.*, 2018; 51(6): 1077–1092.
12. Thakar A., Gupta M.P., Srivastava A., Agrawal D., Kumar A.: Nonsurgical Treatment for Posttraumatic Complete Facial Nerve Paralysis. *JAMA Otolaryngol Head Neck Surg.*, 2018; 144(4): 315–321.
13. Chang C.Y., Cass S.P.: Management of facial nerve injury due to temporal bone trauma. *Am J Otol* 1999; 20(1): 96–114.
14. Hato N., Nota J., Hakuba N., Gyo K., Yanagihara N.: Facial Nerve Decompression Surgery in Patients With Temporal Bone Trauma: Analysis of 66 Cases. *J Trauma.*, 2011; 71(6): 1789–1793.
15. Quaranta A., Campobasso G., Piazza F., Quaranta N., Salonna I.: Facial nerve paralysis in temporal bone fractures: outcomes after late decompression surgery. *Acta Otolaryngol.*, 2001; 121(5): 652–655.
16. Andresen N.S., Sun D.Q., Hansen M.R.: Facial nerve decompression. *Curr Opin Otolaryngol Head Neck Surg.*, 2018; 26(5): 280–285.
17. Nash J.J., Friedland D.R., Boorsma K.J., Rhee J.S.: Management and outcomes of facial paralysis from intratemporal blunt trauma: a systematic review. *Laryngoscope*, 2010; 120(7): 1397–1404.
18. Guntinas-Lichius O., Volk G.F., Olsen K.D., et al.: Facial nerve electrodiagnostics for patients with facial palsy: a clinical practice guideline. *Eur Arch Otorhinolaryngol.*, 2020; 277(7): 1855–1874.
19. Ulug T., Ulubil S.A.: Management of facial paralysis in temporal bone fractures: a prospective study analyzing 11 operated fractures. *Am J Otolaryngol*, 2005; 26(4): 230–238.
20. Andresen N.S., Zhu V., Lee A. et al.: Electrodiagnostic testing in acute facial palsy: Outcomes and comparison of methods. *Laryngoscope Investig Otolaryngol.*, 2020; 5(5): 928–935.
21. Honnurappa V., Vijayendra V.K., Mahajan N., Redlaef M.: Facial Nerve Decompression After Temporal Bone Fracture – The Bangalore Protocol. *Front. Neurol*, 2019; 10: 1067.
22. Panda N.K., Mehra Y.N., Mann S.B., Mehta S.K.: Post traumatic facial paralysis – a review. *JPMA*, 1991; 41: 105–107.
23. Chen Y., Zhang K., Xu Y. et al.: Reliability of temporal bone high-resolution CT in patients with facial paralysis in temporal bone fracture. *Am J Otolaryngol*. 2018; 39(2): 150–152.
24. Kahinga A.A., Han J.H., Moon S.: Total Transcanal Endoscopic Facial Nerve Decompression for Traumatic Facial Nerve Palsy. *Yonsei Med J*, 2018; 59(3): 357–460.
25. Chao J.R., Chang J., Lee J.H.: Extended Epitympanotomy for Facial Nerve Decompression as a Minimally Invasive Approach. *J Audiol Otol.*, 2019; 23(4): 204–209.
26. Soloperto D., Di Maro F., Le Pera B., Marchioni D.: Surgical anatomy of the facial nerve: from middle cranial fossa approach to endoscopic approach. A pictorial review. *Eur Arch Otorhinolaryngol*, 2020; 277(5): 1315–1332.
27. Irugu D.V.K., Singh A., Ch S. et al.: Comparison between early and delayed facial nerve decompression in traumatic facial nerve paralysis – A retrospective study. *Codas.*, 2018; 30(1): e20170063.
28. Abbaszadeh-Kasbi A., Kouhi A., Ashtiani M.T.K. et al.: Conservative versus Surgical Therapy in Managing Patients with Facial Nerve Palsy Due to the Temporal Bone Fracture. *Craniofacial Trauma Reconstr.*, 2019; 12(1): 20–26.

Word count: 3051

Tables: 1

Figures: 2

References: 28

DOI: 10.5604/01.3001.0014.7446 Table of content: <https://otolaryngologypl.com/issue/13862>

Copyright: Some right reserved: Polish Society of Otorhinolaryngologists Head and Neck Surgeons. Published by Index Copernicus Sp. z o.o.

Competing interests: The authors declare that they have no competing interests.



The content of the journal „Polish Society of Otorhinolaryngologists Head and Neck Surgeons” is circulated on the basis of the Open Access which means free and limitless access to scientific data.

This material is available under the Creative Commons – Attribution-NonCommercial 4.0 International (CC BY-NC 4.0). The full terms of this license are available on: <https://creativecommons.org/licenses/by-nc/4.0/legalcode>

Corresponding author: Joanna Marszał MD; Department of Otolaryngology and Laryngological Oncology, Medical University of Poznan; Przybyszewskiego street 49, 60-355 Poznan, Poland; Phone: +48 61 8691387; E-mail: joan.marszal@gmail.com

Cite this article as: Marszał J., Bartochowska A., Gawecki W., Wierzbicka M.: Efficacy of surgical treatment in patients with post-traumatic facial nerve palsy; *Otolaryngol Pol*, 2021; 75 (4): 1–6

