

# Juvenile psammomatoid ossifying fibroma – case report

## Młodzieńczy piaszczakowaty włókniak kostniejący – opis przypadku

**Authors' Contribution:**

A – Study Design  
B – Data Collection  
C – Statistical Analysis  
D – Manuscript Preparation  
E – Literature Search  
F – Funds Collection

Magdalena Kuźmińska<sup>ADEF</sup>, Tomasz Gotlib<sup>E</sup>, Kazimierz Niemczyk<sup>E</sup>

Chair and Clinic of Otorhinolaryngology, Head and Neck Surgery, Medical University of Warsaw, Poland;  
Head: prof. Kazimierz Niemczyk MD PhD

Article history: Received: 10.12.2020 Accepted: 21.01.2021 Published: 22.01.2021

**ABSTRACT:**

**Introduction:** Juvenile psammomatoid ossifying fibroma is a rare benign head and neck neoplasm that develops most commonly in children and young adults in the nasal cavity, paranasal sinuses or the orbit. It can have a locally malignant character with a tendency to destroy surrounding structures. The treatment of choice is surgical removal of the lesion. Depending on the location of the tumor and surgeon's preferences, it is recommended to use endoscopic or external approach, with the first one being the procedure of choice. Considering the risk of massive intraoperative bleeding, it is necessary to protect blood products before surgery.

**Case report:** We present a case of a 41-year-old patient treated in the Department of Otorhinolaryngology, Head and Neck Surgery of the Medical University of Warsaw.

**KEYWORDS:**

endoscopic sinus surgery, juvenile ossifying psammomatoid fibroma, nasal cavity neoplasms, ossifying fibroma, paranasal sinuses neoplasms

**STRESZCZENIE:**

**Wstęp:** Młodzieńczy piaszczakowaty włókniak kostniejący jest rzadko występującym nowotworem łagodnym głowy i szyi, rozwijającym się najczęściej u dzieci i młodych dorosłych w obrębie jamy nosowej, w zatokach przynosowych bądź oczodole. Może przybierać charakter miejscowo złośliwy z tendencją do niszczenia struktur sąsiednich. Leczeniem z wyboru jest operacyjne usunięcie zmiany. W zależności od umiejscowienia guza i preferencji chirurga, zaleca się stosowanie dostępów endoskopowych lub dostępów zewnętrznych, wskazując na te pierwsze jako postępowanie z wyboru. Mając na uwadze ryzyko masywnego krwawienia śródoperacyjnego, przed zabiegiem konieczne jest zabezpieczenie preparatów krwiopochodnych.

**Opis przypadku:** W pracy przedstawiono przypadek 41-letniego pacjenta leczonego w Klinice Otorhinolaryngologii, Chirurgii Głowy i Szyi WUM.

**SŁOWA KLUCZOWE:**

chirurgia endoskopowa zatok przynosowych, guzy jamy nosowej, guzy zatok przynosowych, młodzieńczy piaszczakowaty włókniak kostniejący, włókniak kostniejący

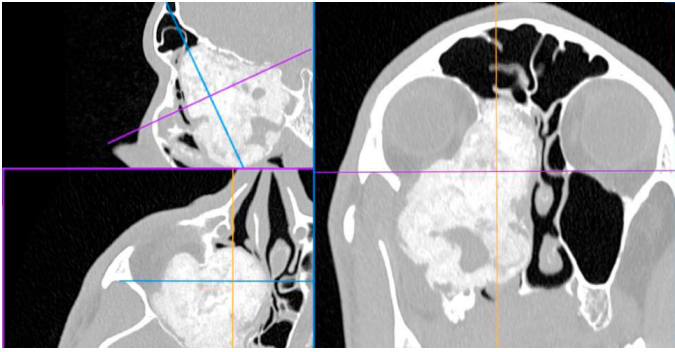
## INTRODUCTION

Juvenile ossifying fibroma is a rare benign lesion, one of many osteo-fibrotic tumours of the head and neck area. As the name indicates, it is usually diagnosed at puberty, in 79% of patients under 15 years of age, although it can also develop in adults [1, 2]. According to the WHO classification of dental tumours of 2017 juvenile psammomatoid ossifying fibroma was classified as a variant of craniofacial ossifying fibroma with distinctive features regarding the age of occurrence, location and clinical and anatomopathological characteristics [3].

In the study by Narożny (1999), the diagnosis of ossifying fibroma was made in 3 out of 163 patients with benign neoplasms of the nose and paranasal sinuses (1.8%) [4].

Juvenile psammomatoid ossifying fibroma is usually diagnosed in children and young adults. The characteristic locations are: nasal cavity, paranasal sinuses, orbits or the fronto-ethmoid complex; it extremely rarely develops in the base or the vault of the skull [5].

The look of the lesion on imaging may lead to the correct diagnosis, but it is not easy due to the similarities it shows with other osteo-fibroid lesions of facial skeleton. Histopathologically juvenile psammomatoid ossifying fibroma is characterized by a fibrous cellular stroma with fine, homogeneous, spherical, calcified inclusions which resemble psammoma bodies [5, 6]. Despite the fact that juvenile psammomatoid ossifying fibroma is a benign and slowly growing lesion, it is locally malignant with a tendency to infiltrate



**Fig. 1.** Preoperative computed tomography images showing a tumour of ossifying fibroma type.

surrounding structures, therefore it is important to make appropriate diagnosis and implement treatment, which should be complete tumour removal. Non-radical or partial resection is associated with a high recurrence rate.

This article presents a case of juvenile psammomatoid ossifying fibroma diagnosed in an adult.

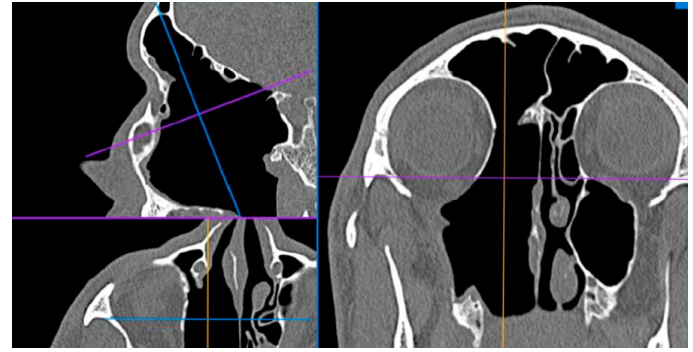
## CASE REPORT

A 41-year-old patient was referred to the Department of Otorhinolaryngology, Head and Neck Surgery of the Medical University of Warsaw from a different centre with a diagnosis of juvenile angiofibroma with a request to proceed with embolization and further treatment. Histopathology examination of the maxillary sinus tumour carried out in the referring centre however diagnosed the lesion to be of psammomatoid juvenile ossifying fibroma type.

Except lasting for 2 years nasal obstruction on the right, the patient was also reporting sensation of expansion in the right suborbital area as well and right eye proptosis and face asymmetry. Patient's symptoms got worse a few months before his hospitalization. Patient denied epistaxis or diplopia. He reported impaired vision in the right eye present since childhood. Rhinoscopy showed the right nasal cavity filled with a tissue mass. No pathology was found on the opposite side. Except for right proptosis, no abnormal findings were present during further parts of ENT examination. Eye assessment showed short-sightedness and astigmatism of the right eye with pseudo-proptosis, preserved movements of eyeballs, right retinal thinning. No other significant abnormal findings were seen on eye sight examination. No significant abnormalities were found on laboratory tests.

Imaging carried out before hospital admission (computed tomography and nuclear magnetic resonance) showed a pathological mass occupying the right maxillary and nasal cavity, penetrating to the pterygopalatine fossa, infratemporal fossa, convexing into the right orbit and causing destruction of its inferior and medial wall, encasing anterior ethmoid to the frontal recess and right sphenoid sinus with segmental destruction of bone framing of the internal carotid artery and the base of the anterior and middle cranial fossa (Fig. 1.).

Due to known risk of perioperative bleeding, blood products were ordered preoperatively. Surgical removal of the tumour was



**Fig. 2.** Images of computed tomography of paranasal sinuses in 3MPR reconstruction post-surgical treatment.

carried out through intranasal approach under 30 degree endoscopic optical supervision. A tumour mass of bone texture covered with intact mucous membrane was found in the right nasal cavity. The tumour was heavily bleeding and subsiding under curette pressure. A part of the tumour was removed from the anterior ethmoid, the frontal sinus was opened and the tumour was removed from the upper part of the nasopharynx and maxillary sinus. Deformed by the tumour lamina papyracea was stripped. Due to massive haemorrhage from the whole surface of the tumour (2.4 litre of blood loss within a short period of time) and risk of the internal carotid artery and optic nerve damage the operation was ceased under conditions of poor visibility. Abilities to proceed with tumour coagulation were significantly limited during surgery due to the blood vessels penetrating deeply into the tumour tissue. Bilateral anterior nasal packing was applied. During postoperative period no bleeding or impaired eyeball movement was observed. Packed red blood cell concentrate was transfused, antibiotic therapy was continued and the patient was prepared to undergo the removal of nasal packing in theatre. After the nasal packing was removed massive haemorrhage was observed from the area of the Vidian artery. In view of ineffective coagulation and rapid blood loss bilateral anterior nasal packing was applied again and blood vessel embolization was carried out. On digital subtractive angiography remnant tumour was visualized supplied with blood by two wide sphenopalatine arteries and left anterior ethmoidal artery. Additional vasularisation came from the right anterior ethmoidal artery and right accessory meningeal artery. Embolization of sphenopalatine arteries was conducted. Tumour resection was performed on the next day. No excessive bleeding was seen during the operation. The part of the tumour adjacent to the anterior wall of the maxillary sinus was removed, the tumour was separated from the periosteum of the orbit, a fragment of the tumour was resected from the infratemporal fossa, then the tumour was detached from the posterior part of the nasal septum and the sphenoid sinus filled with mucus was opened. The part of the tumour covering the optic nerve was removed and then the part of the tumour adjacent to the middle turbinate; the frontal sinus opening was widened and cleared of tumour remnants. After tumour removal, the cavity was filled with Surgicel and Spongostane and an anterior tamponade was placed. The postoperative period was uneventful. Six months after the operation, the residual tumour fragments were removed from the anterior wall of the maxillary sinus under general anesthesia. The patient has been under observation for 36 months, so far without recurrence (Fig. 2.).

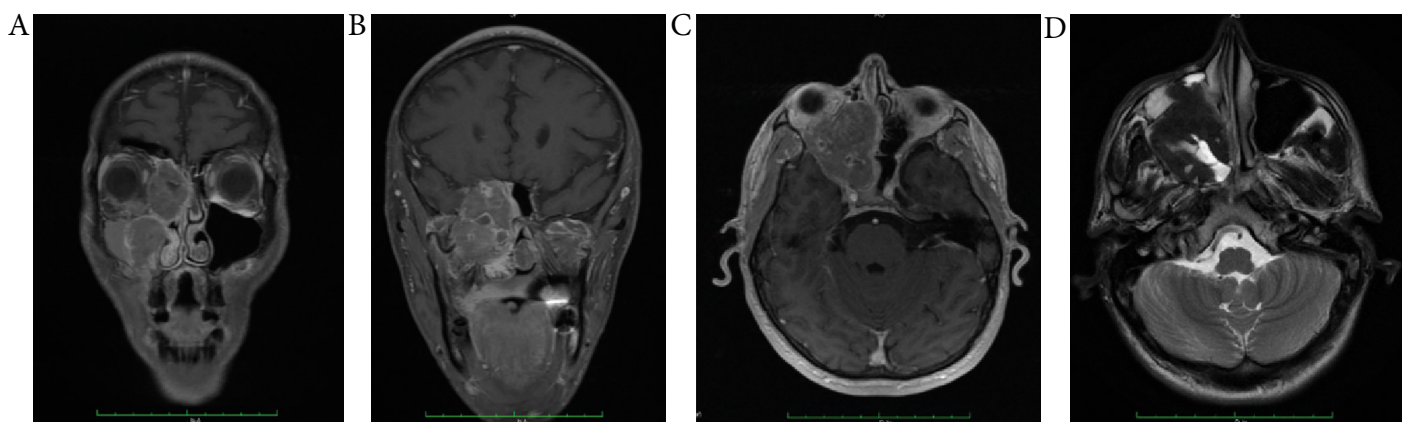


Fig. 3. (A–D) Preoperative imaging by magnetic resonance. (A–C) Scans in T1 sequence with contrast, (D) in T2 sequence.

## DISCUSSION

The name juvenile psammomatoid ossifying fibroma is a result of many years of controversy over nomenclature. The tumour of such type was described for the first time in 1938 by Benjamins who used the term *osseus* fibroma with atypical ossification. In 1949 Gögl named the neoplasm *psammomatoid ossifying fibroma* and a few years later Johansson introduced the name *juvenile active ossifying fibroma* which was to mark the aggressive proliferative nature of the process. Multiple modifications of the nomenclature were taking place till 2005 when in WHO classification of odontogenic and maxillofacial bone tumors fibrotic dysplasia, osseous dysplasia and ossifying fibroma were specified amongst benign osseous fibrotic neoplasms of head and neck. Ossifying fibromas can be divided into classic and juvenile forms and amongst the latter there are two separate histopathological forms: trabecular (juvenile trabecular ossifying fibroma) and psammomatoid (juvenile psammomatoid ossifying fibroma) [3]. It should be emphasized that the characteristic histological and clinical features of the tumour make juvenile psammomatoid ossifying fibroma a pathology completely separate from juvenile angiofibroma, however, heterogeneous nomenclature and rare use of the Polish terminology could be the reason for incorrect diagnosis used in this case in the referral letter to the hospital.

Osteo-fibrotic lesions of the facial skeleton constitute a group of pathologies characterized by the replacement of bone tissue with a benign connective tissue matrix containing a varying amount of mineralized substance. According to Johnson, juvenile psammomatoid ossifying fibroma may originate from the area of cranial sutures, others emphasize the role of overproduction of mucopolysaccharide cell stroma. The abnormal stromal cells produce hyaline substance which can ossify [5]. In recent years, the role of HRPT2 gene mutation has been also postulated in the pathogenesis of ossifying fibroma [7].

Both singular as well as series of juvenile psammomatoid ossifying fibroma are described in the literature. The most numerous of them, presented by Johnson et al. and Makek, included 112 and 86 patients respectively and described two typical age ranges of tumour occurrence: 10–15 and 25–30 years of age, although numerous cases, similar to the one described in this paper, affected

the elderly. A slight predominance in males was observed. The most common locations of the tumour were the paranasal sinuses (70%), the jaw (20%) and the mandible, only in a few cases – bones of the neurocranium [8, 9].

Juvenile psammomatoid ossifying fibroma usually develops asymptotically without neurological deficits, however it depends on its location. In the case of location within the facial skeleton proptosis is the most common symptom [8]. Lateral displacement of the eyeball and visual acuity impairment have been also reported on. Symptoms of nasal sinus involvement include nasal blockage, recurrent sinusitis, facial pain and swelling. Painless swelling of the lower jaw may be an indicator of the involvement of that area. The tumour is characterized by slow growth, but it can occupy adjacent areas by displacing the tissues until it invades and destroys the bone tissue. Intracranial growth may be the cause of some described complications such as encephalitis or meningitis [9]. It is also possible, especially in patients in the 1<sup>st</sup> or 2<sup>nd</sup> decade of life, for the tumour to show an aggressive growth. It is especially characteristic for the mandibular location and is associated with the formation of aneurysmal bone cysts. Despite the risk of aggressive growth or recurrence, no case of malignant transformation or metastases has been reported on so far [5, 9].

Recommended imaging tests for juvenile psammomatoid ossifying fibroma include computed tomography in bone window and magnetic resonance. Computed tomography shows an expansive but well-defined lesion, composed of thick bone tissue in the margins, often polycystic inside and containing areas of the „milk glass” type. The abnormal bone tissue of the tumour is not difficult to distinguish from the surrounding bones. MRI in the T1 sequence shows a gray matter-like signal and decreased intensity of the signal in T2 sequence. Within the mandible, a limited or extensive lesion with calcified matrix can be seen, in the area of the paranasal sinuses – mass with well-defined margins penetrating into the aerated spaces, although there are cases of blurring of the boundaries [5].

Juvenile psammomatoid ossifying fibroma belongs to the group of benign osteo-fibrotic lesions with common histopathological features, including the presence of rich-cell fibroblast stroma with numerous calcifications and foci of ossification. The presence of multiple, spherical, homogeneous inclusions with concentric

calcifications resembling psammomatoid bodies is characteristic. Mitotic figures are extremely rare, atypia or foci of necrosis are not observed [10].

Differentiation should take into account fibrous dysplasia, which is an osteo-fibrotic process characterized by a progression different from that of juvenile ossifying fibroma and as opposed to it manifesting as a unifocal or multifocal poorly defined proliferative lesion; active form of fibrotic dysplasia may, however, be radiologically indistinguishable and proper diagnosis is possible only with the cooperation of a clinician, radiologist and pathologist [11, 12]. Other lesions that juvenile psammomatoid ossifying fibroma should be differentiated with are neoplasms forming cement or cement-like tissue: benign osteoma (cementoblastoma) and cementifying fibroma, usually occurring in the 3<sup>rd</sup> and 4<sup>th</sup> decade of life and developing in the premolars and molars of the mandible, psammomatoid meningioma and in children primary intraosseous cavernous haemangioma or eosinophilic granuloma [5].

Despite clinical and radiological features supporting the diagnosis of juvenile psammomatoid ossifying fibroma, if the lesion is endoscopically amenable, it is advisable to proceed with a biopsy for histopathological examination to rule out its malignant nature. Some malignant neoplasms such as sarcoma may show features of sclerotization, erosion and bone destruction as well as calcified or osseous inclusions, which may make differential diagnosis difficult [13].

The treatment of choice is complete surgical removal of the lesion. This can be challenging for surgeons because juvenile psammomatoid ossifying fibromas are characterized by rich vascularization as well as adherence to the dura mater or periosteum of the orbit [13]. To prevent relapse, a diamond drill is to be used to scrape the outer layer of the tumour until it reaches smooth, healthy bone with less brittle consistency [14]. Recurrence after partial or incomplete resection is common (30–56%) [3, 6, 15] and the time during which recurrence can be observed ranges from 6 months to even 19 years after surgery [6]. Increased risk of recurrence relates to tumours causing significant bone destruction and periosteal elevation as well as located in areas of difficult surgical access, which makes complete resection impossible. Depending on the location of the lesion and surgeon's preferences, it is recommended to use external or endoscopic approach alone or in combination with open access [16]. In recent years, the procedure of choice has been postulated to be performed by endoscopic operations, leaving the use of external accesses for cases of involvement of the anterior wall of the frontal sinus or supraorbital recess, lesions surrounding the optic nerve or including the skull base laterally to the optic nerve [13].

Described complications of surgery include significant intraoperative blood loss requiring a transfusion and complications secondary

to the destruction of vital anatomical structures [17]. Nevertheless, preoperative embolization is not postulated. Some authors recommend avoiding it even in the case of vascularized lesions, especially in the close proximity of the orbit, due to the risk of blindness caused by numerous connections of the vessels supplying the tumour and branches of the ophthalmic artery [13]. In the presented case, embolization was necessary due to massive bleeding.

In Wang's study of a series of 31 cases of ossifying fibromas of paranasal sinuses which were operated on endoscopically, the correlation between the severity of bleeding and the duration of the operation was confirmed. The primary abundant vascularization of the tumour and the histopathology of the lesion, often including aneurysmal cysts within, were also important as a result of the fact that the tumour removed under endoscopic guidance, „piece by piece” often was showing a tendency to a massive bleeding. Techniques to reduce perioperative bleeding include applying pressure on the bleeding site, for example by applying a gas seton, electrocoagulation and transfusion of coagulation factors. To avoid the need for a blood transfusion, the anaesthetist should administer large volumes of crystalloids intravenously before the surgery to rapidly increase the blood volume and continue anaesthesia under controlled hypotension during the procedure. Despite actions taken, sometimes massive bleeding would not allow the operation and lead to its termination [14].

Regardless of the surgical approach used, regular clinical and radiological check-ups should be performed following surgery to detect and treat any recurrence. In case of primarily non-radical resection, adjuvant treatment is not recommended due to radio-resistance of juvenile psammomatoid ossifying fibroma, although there have been reports of efficacy of such procedures [18]. The benign nature of the lesion prevents use of chemotherapy [10]. Despite the lack of detailed guidelines on the frequency of follow-up visits and further management, it is always worth considering re-surgery in case of recurrence.

## CONCLUSIONS

1. Juvenile psammomatoid ossifying fibroma is a benign, bone-related lesion that can be locally malignant with a tendency to destroy surrounding anatomical structures;
2. The treatment course includes complete removal of the lesion with the use of endoscopic or external approach;
3. Due to the risk of profuse perioperative bleeding, it is necessary to secure blood products before surgery;
4. After surgery, regular, long-term outpatient follow-ups are recommended. If a recurrence is diagnosed, surgical re-treatment should be considered.

## References

1. Aggarwal S., Garg A., Aggarwal A., Ahuja N., Rehman F.: Juvenile ossifying fibroma: Psammomatoid variant. *Contemp Clin Dent.*, 2012; 3(3): 330–333.
2. Bielecki I., Mniszek J., Zielińska-Pajak E., Pajak J., Kluczevska E., Zygan L.: Cemento-ossifying fibroma – opis dwóch przypadków i przegląd literatury. *Otolaryngol Pol*, 2005; 59(1): 109–114.
3. El-Naggar A.K., Chan J.K.C., Grandis J.R., Takata T., Slotweg P.J.: *World Health Organization Classification of Tumours*. Lyon, France: 4th Edition 2017: 251–252.
4. Narożny W., Stankiewicz Cz., Oździński W., Skorek A., Kamiński M.: Włókniak kostniejący szczęki o nietypowym obrazie klinicznym. *Czas. Stoma*, 1999; 52(5): 326–330.



5. López C.B., Zabala A.B., Bareño E.U.: Cranial juvenile psammomatoid ossifying fibroma: case report. *J Neurosurg pediatr*, 2016; 17: 318–323.
6. Bertrand B., Eloy P., Cornelis J.P. et al.: Juvenile aggressive cemento-ossifying fibroma: case report and review of the literature. *Laryngoscope*, 1993; 103: 1385–1390.
7. Pimenta F.J., Gontijo Silveira L.F., Tavares G.C. et al.: HRPT2 gene alterations in ossifying fibroma of the jaws. *Oral Oncol.*, 2006; 42: 735–739.
8. Makek M.: *Clinical Pathology of Fibro-Osteo-Cemental Lesions of the Cranio-Facial Skeleton and Jaw Bones*. Basel, Switzerland: Karger 1983: 128–227.
9. Johnson L.C., Youse M., Vinh T.N. et al.: Juvenile active ossifying fibroma. Its nature, dynamics and origin. *Acta Otolaryngol Suppl*, 1991; 488: 1–40.
10. Sarode S.C., Sarode G.S., Wanknis P., Patil A., Jashika M.: Juvenile psammomatoid ossifying fibroma: a review. *Oral Oncol*, 2011; 47: 1110–1116.
11. Harnsberger H.R., Hudgins P., Wiggins R., Davidson H.C.: 100 rozpoznaj Głowa i szyja. Medipage, Warszawa 2007: 155–157.
12. Papadaki M.E., Troulis M.J., Kaban L.B.: Advances in diagnosis and management of fibro-osseous lesions. *Oral Maxillofac Surg Clin N Am*, 2005; 17(4): 415–434.
13. Ciniglio Appiani M., Verillaud B., Bresson D. et al.: Ossifying fibromas of the paranasal sinuses: diagnosis and management. *Acta Otorhinolaryngologica Italica: Organo Ufficiale Della Societa Italiana di Otorinolaringologia e Chirurgia Cervico-facciale*, 2015; 35(5): 355–361.
14. Wang H., Sun X., Liu Q., Wang J., Wang D.: Endoscopic resection of sinonasal ossifying fibroma: 31 cases report at an institution. *Eur Arch Otorhinolaryngol*, 2014; 271: 2975–2982.
15. Figen A., Hasmet Y., Eren A.: Psammomatoid variant of juvenile ossifying fibroma. *Indian J Pathol Microbiol*, 2018; 61(3): 443–445.
16. Rowland N.C., Jermakowicz W.J., Tihan T., El-Sayed I.H., Mc-Dermott M.W.: Subacute cystic expansion of intracranial juvenile psammomatoid ossifying fibroma. *J Neurosurg Pediatr*, 2013; 11: 687–691.
17. Noffke C.E.: Juvenile ossifying fibroma of the mandible. An 8-year radiological follow-up. *Dentomaxillofac Radiol*, 1998; 27: 363–366.
18. Strickler S., Hitchcock K.E., Dziegielewski P.T., Mendenhall W.M.: Radiotherapy for juvenile ossifying fibroma of the maxillary sinus: Case report and literature review. *Head Neck*, 2017; 39(8): E81–E84.


Word count: 2738 Tables: – Figures: 3 References: 18

Access the article online: DOI: 10.5604/01.3001.0014.6993

Table of content: <https://otorhinolaryngologypl.com/issue/13697>

Some right reserved: Polish Society of Otorhinolaryngologists Head and Neck Surgeons. Published by Index Copernicus Sp. z o.o.

Competing interests: The authors declare that they have no competing interests

 The content of the journal „Polish Society of Otorhinolaryngologists Head and Neck Surgeons” is circulated on the basis of the Open Access which means free and limitless access to scientific data.



This material is available under the Creative Commons – Attribution-NonCommercial 4.0 International (CC BY-NC 4.0). The full terms of this license are available on: <https://creativecommons.org/licenses/by-nc/4.0/legalcode>

Corresponding author: Magdalena Kuźmińska MD PhD; Chair and Clinic of Otorhinolaryngology, Head and Neck Surgery, Medical University of Warsaw; Banacha street 1a, 02-097 Warsaw, Poland; Phone: +48 (22) 599 25 21; E-mail: [magdalena.kuzminska@wum.edu.pl](mailto:magdalena.kuzminska@wum.edu.pl)

Cite this article as: Kuzminska M., Gotlib T., Niemczyk K.: Juvenile psammomatoid ossifying fibroma – case report; *Pol Otorhino Rev* 2021; 10 (1): 57-61