

# Myopia. Definition and classification according to the latest knowledge

Magdalena Durajczyk<sup>1</sup>, Ewa Grudzińska<sup>1</sup>,  
Aleksandra Obszańska<sup>2</sup>, Monika Modrzejewska<sup>1</sup>

<sup>1</sup>II Chair and Department of Ophthalmology,  
Pomeranian Medical University in Szczecin in Poland  
Head: Prof. Wojciech Lubiński, MD, PhD, FEBO

<sup>2</sup>Jan Bogdanowicz Children's Hospital in Warsaw in Poland



## HIGHLIGHTS

Using uniform definitions and the division of myopia would make it easier for scientists to compare research results and further develop this field of science.

## ABSTRACT

Myopia is the main cause of vision decrease, being the most common refractive error. There are many classifications of myopia based on the size of refractive error, heredity, time of onset, fundus details and axial length of the eyeball. There is a great deal of inconsistency in the literature in this regard. Many descriptive terms as well as classifications defining types of myopia can be found, which leads to difficulties when comparing research results. The purpose of this article is to present the current definition and classification of myopia based on a review of the PubMed literature from the last 5 years.

**Key words:** myopia, definitions, classification, refractive errors

## INTRODUCTION

Short-sightedness is a global public health problem and a major cause of visual impairment, being the most common refractive error in children under 6 years of age, adolescents and young adults. It currently affects at least 30% of the population worldwide, and the prevalence of this refractive error has been steadily increasing in recent years. It is predicted that by 2050, 5 billion people worldwide will be short-sighted [1]. In the extensive literature on this topic, myopia is defined as a refractive defect of  $-0.50$  D spherical equivalent or less [1]. Myopia is recognized as a risk factor responsible for a number of other serious ocular complications [2]. Although there are many ways to correct blurred vision in patients with myopia, these simple corrective strategies cannot stop the concomitant progressive pathologic changes of the eyeball and progression of myopia [3]. Many years of research related to myopia have identified many risk factors for this disease, such as a positive family history of myopia, living in urban areas, lack of outdoor time, reduced hours of sleep, and reduced blood levels of vitamin  $D_3$  [4].

Researchers are now highlighting two major modifiable risk factors for myopia: time spent outdoors and education [5]. These two factors provide a clinical evidence-based perspective offering the possibility of inhibiting the increase in myopia by increasing time spent outdoors and possibly decreasing time working from close distances and patient education.

In today's era of evidence-based medicine, the different terms and classifications of myopia present a significant obstacle when trying to compare epidemiological studies. To date, the field of myopia has lacked internationally agreed standardized classifications, such as exist in retinopathy of prematurity, among others.

The purpose of this article is to present the current definition and classification of myopia based on a review of the PubMed literature over the past 5 years.

## MYOPIA – DEFINITION

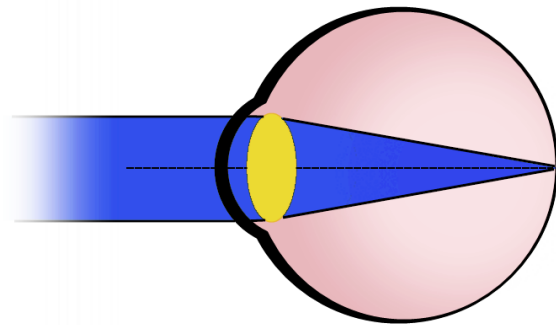
In the literature, the definition of the optical aspect of myopia, is rather consistent, although the choice of words sometimes varies.

The World Health Organization (WHO) International Classification of Diseases (ICD-10) defines myopia as a refractive error in which light rays running parallel to the optical axis are focused in front of the retina when accommodation is in a relaxed state [2]. This is because the refractive state of the eye is determined by the axial length of the eyeball in relation to the refractive power of the eye's optical system. In the case of slight myopia, there is a slight shortening of the focal length of the optical system or a slight increase in the length of the eyeball. In contrast, in moderate to high

myopia, the most common deviation found is an elongation of the axial length of the eyeball. In contrast to myopia, in a normal eyeball with relaxed accommodation, parallel incident light rays are focused on the retina, resulting in a sharp image of the object under observation (fig. 1) [6].

FIGURE 1

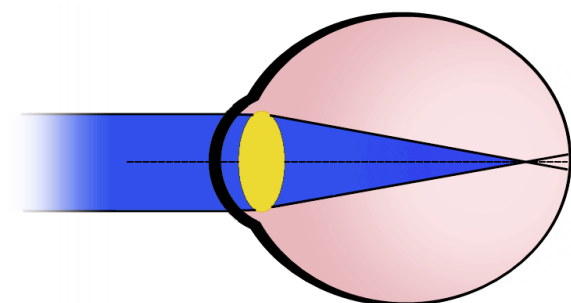
Schematic showing the emmetropic eye. Light rays with relaxed accommodation are focused on the retina.



In the case of the myopic eye, with relaxed accommodation, parallel incident light rays are focused in front of the retina, resulting in a blurred image when looking into the distance (fig. 2).

FIGURE 2

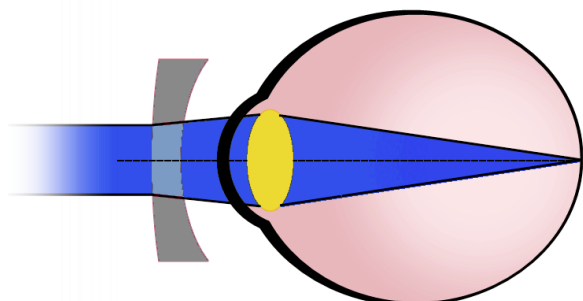
Diagram showing a myopic eye. Light rays with relaxed accommodation are focused in front of the retina.



Acquiring sharp distance vision in myopia is possible with distracting (minus) lenses in the form of glasses, contact lenses, or by performing procedures that modify the optical curvature of the cornea, during which its optical power is lowered (fig. 3).

FIGURE 3

Diagram showing a myopic eye with refractive error corrected with an ocular lens. Light rays with relaxed accommodation are focused on the retina.



The process of myopia onset remains unclear. It is considered that it may be the result of a failure of the emmetropization process secondary to an attempt to eliminate the relative hyperopic blur that is present at the periphery of the elliptical eyeball. The emmetropization process itself involves the adjustment of the length of the eye's optical axis to the optical properties of the cornea and lens, which occurs after the end of the second year of life. Until the end of the second year of life, the eyeball grows spherically. In contrast, the elongation of the eyeball during emmetropization after the second year of life is associated with retinal thinning and decreased retinal pigment epithelium (RPE) cell density in and posterior to the equatorial region, as well as choroidal and scleral thinning beginning at the equator and most pronounced within the posterior pole of the eyeball. However, retinal thickness and RPE density in the macular region are independent of axial eyeball length. The axial length of the eyeball also does not affect the thickness of Bruch's membrane (BM). It is still unclear in which tissue the primary lesion causing eyeball elongation originates. Candidate factors include the retina, retinal pigment epithelium, Bruch's membrane, choroid and/or sclera [7].

### MYOPIA – DIVISION

Myopia was already the topic of Aristotle's philosophical considerations, as well as the concept of Johannes Kepler's research work in 1604. The great interest in the subject of myopia among scientists over the centuries caused that it was defined in many different ways: with regard to its presumed etiology, onset (age) of the disease, size of the refractive defect, and structural changes of the eyeball [2].

The large amount of literature available on this refractive defect has revealed a diversity of definitions. An example of this is the frequently used term *pathologic (degenerative) myopia* which is often confused with the term *high myopia* which is a mistake because high myopia is defined as a high degree of refractive defect while *pathologic myopia* is char-

acterized by the presence of typical features of myopia in the posterior pole of the eye [6].

In the past, the classification most frequently mentioned in the literature was the division introduced by Grosvenor [6, 8]. He divided myopia by age-related occurrence, based on the period in which it appears. He distinguished between:

1. Congenital myopia – present at birth and remains throughout life.
2. Youth-onset myopia – occurs between the ages of 5 and 20.
3. Early adult-onset myopia – occurs between the ages of 20 and 40.
4. Late adult-onset – occurs at age 40 and older.

At the initiative of the International Myopia Institute (IMI), researchers are proposing a set of definitions for myopia that are based on clinical evidence. Researchers have divided myopia qualitatively and quantitatively (tab. 1).

TABLE 1

Classification of myopia according to the International Myopia Institute (based on [2]).

Term	Definition
<b>Qualitative definition</b>	
Myopia	A refractive error in which light rays running parallel to the optical axis are focused in front of the retina when accommodation is in a relaxed state. This is usually due to an overly long eyeball axis, but can also be caused by an overly curved cornea and/or a lens with increased optical power.
Axial myopia	A refractive defect resulting mainly from a larger than normal axial length of the eyeball.
Refractive myopia	A refractive error that can be attributed to changes in the structures or location of the elements of the eye through which light rays pass, such as the cornea and lens.
Secondary myopia	A refractive defect for which there is a specific cause (e.g., drug, corneal disease, or systemic clinical syndrome) that can be identified but is not thought to be a population factor in the development of myopia, e.g., corneal cone.
<b>Quantitative definition</b>	
Myopia	Refractive error less than or equal to -0.50 D with relaxed accommodation of the eye.
Low myopia	Refractive errors from -0.5 D to > -6.0 D with relaxed accommodation.
High myopia	Refractive error less than or equal to -6.0 D with relaxed accommodation.

Pre-myopia	Refractive status in children from +0.75 D to > -0.50 D, in which the combination of the underlying refractive defect, age and other measurable risk factors for developing myopia carries a sufficient likelihood of developing myopia in the future and therefore merits preventive interventions.
------------	--

The division described by the American Optometric Association (AOA) based on clinical units distinguishes [9]:

1. Simple myopia: refers to an eyeball that is too long in relation to its optical power or, less commonly, has too much optical power in relation to its length, with no other deviations from normal. Simple myopia is usually less than 6 diopters. It is the most common type of myopia.
2. Night myopia: occurs only in low light conditions. It is caused by an increased accommodative response associated with reduced light levels. The lowered contrast is an insufficient accommodative stimulus, causing the eye to assume an intermediate accommodative position in the dark instead of focusing on infinity.
3. Degenerative myopia otherwise known as pathologic myopia: is associated with the presence of degenerative changes in the back of the eye. These changes can lead to a decrease in best-corrected visual acuity or changes in the visual field. It is relatively often associated with dangerous complications such as glaucoma or retinal detachment.
4. Induced or acquired myopia: it is associated with exposure to various pharmaceuticals, changes in blood glucose levels, clouding of the lens nucleus and other factors. This type of myopia may only occur temporarily and be reversible.
5. Pseudo-myopia: is the result of over-stimulation of the accommodative system or contraction of the ciliary muscle.

Japanese researchers have proposed a classification system for myopia maculopathy. The use of a uniform classification in different studies will facilitate communication and comparison of the results of clinical trials and epidemiological studies [10]. Due to the lack of a common classification scheme, it has not been possible to directly compare the incidence of individual typical myopic lesions. Furthermore, with the introduction of anti-vascular endothelial growth factor (anti-VEGF) into the treatment of choroidal neovascularization in myopia [11], there was an urgent need to develop a standard photographic classification system with consistent nomenclature.

The classification proposed by the authors adopted a classification based on long-term observational studies to define myopic maculopathy (tab. 2) [6, 12].

TABLE 2

Division of myopia due to changes in the macula (based on [10]).

	Maculopathy in myopia	„Plus” lesions
Category 0	No myopic retinal degenerative lesion	Lc Fs CNV
Category 1	Tessellated fundus	
Category 2	Diffuse chorioretinal atrophy	
Category 3	Patchy chorioretinal atrophy	
Category 4	Macular atrophy	

CNV – choroidal neovascularization; Fs – Fuchs spots; Lc – lacquer cracks.

To simplify the assignment of a clinical condition to a category, the investigators relied on nomenclature uniformity materials available on ajo.com.

- Category 1 – mosaic fundus – is clearly visible choroidal vessels that can be seen around the fovea as well as around the choroidal arcades.
- Category 2 – diffuse choroidal atrophy – are yellowish-white lesions at the posterior pole. If present, estimate their size and extent by comparing to the area of the optic disc as a unit of size.
- Category 3 – patchy choroidal atrophy – is a well-defined, grayish-white lesion in the macular area or around the optic disc.
- Category 4 – macular atrophy – is defined as a well-demarcated, grayish or whitish, round choroidal-retinal lesion in the fovea region. Three additional features – lacquer cracks (Lc), CNV in myopia, and Fuchs spots (Fs) – were considered plus signs.

Fuchs spots are a consequence of CNV in myopia, and lacquer fractures are associated with CNV risk. These three lesions affect central visual acuity. They can coexist with any category of myopia maculopathy, even in the early stages of the disease [10].

## CONCLUSION

Uncorrected refractive errors are the number one cause of visual impairment worldwide, of which myopia is the most common. Using uniform definitions and division of myopia would make it easier for researchers to compare research

results, draw conclusions, and further develop this scientific field.

## CORRESPONDENCE

**Monika Modrzejewska MD, PhD, Professor of Pomeranian Medical University**

II Chair and Department of Ophthalmology,  
Pomeranian Medical University in Szczecin in Poland  
70-111 Szczecin, al. Powstańców Wlkp. 72  
phone: (+48) 91 466 12 93  
e-mail: monika\_modrzej@op.pl

## ORCID

Magdalena Durajczyk – ID – <http://orcid.org/0000-0002-7988-347X>  
Ewa Grudzińska – ID – <http://orcid.org/0000-0002-9335-6764>  
Aleksandra Obszańska – ID – <http://orcid.org/0000-0003-3250-2083>  
Monika Modrzejewska – ID – <http://orcid.org/0000-0002-9221-8909>

## References

1. Holden BA, Fricke TR, Wilson DA et al. Global Prevalence of Myopia and High Myopia and Temporal Trends from 2000 through 2050. *Ophthalmology*. 2016; 123(5): 1036-42.
2. Flitcroft DJ, He M, Jonas JB et al. IMI – Defining and Classifying Myopia: A Proposed Set of Standards for Clinical and Epidemiologic Studies. *Investig Ophthalmology Vis Sci*. 2019; 60(3): M20.
3. Ikuno Y. Overview of the complications of high myopia. *Retina*. 2017; 37(12): 2347-51.
4. Grzybowski A, Kanclerz P, Tsubota K et al. A review on the epidemiology of myopia in school children worldwide. *BMC Ophthalmol*. 2020; 20(1): 27.
5. Morgan IG, Wu P-C, Ostrin LA et al. IMI Risk Factors for Myopia. *Investig Ophthalmology Vis Sci*. 2021; 62(5): 3.
6. Grosvenor TP, Tokarzewski T, Ożóg M et al. *Optometria*. Edra Urban & Partner, Wrocław 2019.
7. Jonas JB, Ohno-Matsui K, Panda-Jonas S. Myopia: Anatomic changes and consequences for its etiology. *Asia-Pac J Ophthalmol*. 2019; 8(5): 355-9.
8. Ahmad I, Qureshi T, Jan R et al. Myopia: Perspectives and challenges. *JK Pr J Curr Clin Med Surg*. 2007; (14): 65-70.
9. Goss DA, Grosvenor TP, Jeffrey OD et al. *Optometric Clinical Practice Guideline Care Of The Patient With Myopia*. Reference Guide for Clinicians Prepared by the American Optometric Association Consensus Panel on Care of the Patient with Myopia: Reviewed by the AOA Clinical Guidelines Coordinating Committee. 2006.
10. Ohno-Matsui K, Kawasaki R, Jonas JB et al. International Photographic Classification and Grading System for Myopic Maculopathy. *Am J Ophthalmol*. 2015; 159(5): 877-83.e7.
11. Wolf S, Balciuniene VJ, Laganovska G et al. RADIANCE: A Randomized Controlled Study of Ranibizumab in Patients with Choroidal Neovascularization Secondary to Pathologic Myopia. *Ophthalmology*. 2014; 121(3): 682-92.e2.
12. Hayashi K, Ohno-Matsui K, Shimada N et al. Long-term Pattern of Progression of Myopic Maculopathy. *Ophthalmology*. 2010; 117(8): 1595-611.e4.

**Authors' contributions:**

Magdalena Durajczyk: drafting the work; Ewa Grudzińska: drafting the work, substantial contributions to the conception of the work; Aleksandra Obszańska: substantial contributions to the conception of the work; Monika Modrzejewska: revising work critically for important intellectual content.

**Conflict of interest:**

None.

**Financial support:**

None.

**Ethics:**

The content presented in the article complies with the principles of the Helsinki Declaration, EU directives and harmonized requirements for biomedical journals.