

# Tibial tuberosity

## Trochlear groove distance in symptom-free young subjects and the proposal for a new guideline value to evaluate patellofemoral pain syndrome in case of trochlea dysplasia

Artykuł recenzowany

**ANDREAS ALK<sup>1,3</sup>,**  
**VIOLA BANTLE<sup>1,2</sup>,**  
**TOBIAS MARTIN<sup>1,3</sup>,**  
**RUI WANG<sup>1,4</sup>,**  
**MARCIN KASPRZYK<sup>5</sup>,**  
**JOSEF KOZAK<sup>1,3</sup>**

<sup>1</sup> Aesculap AG Tuttlingen,  
Germany

<sup>2</sup> Universität Stuttgart, Germany

<sup>3</sup> AGH University of Science and  
Technology Krakow, Poland

<sup>4</sup> Karlsruher Institut  
für Technologie, Germany

<sup>5</sup> Ortopedicum Krakow, Poland

**Keywords:**

patellofemoral pain syndrome  
(PFPS), TT-TG, smartphone-based  
mobile sonography system

### Abstract

*For the evaluation of the patellofemoral pain syndrome (PFPS) the mediolateral distance between the tibial tuberosity and the trochlear groove (TT-TG) is considered as the gold standard. In this work, we propose to replace the measurement of the TT-TG with conventional tomographic or radiological section images by a smartphone-based mobile sonography system. This new system allows to provide not only ultrasound imaging but also a measuring method for determining the TT-TG using a smartphone as a mobile tracking unit. Moreover, the system supports the diagnosis by acquiring an additional parameter: the mediolateral distance between the intercondylar notch and the tibial tuberosity (TT-IN). The distinctive structure of the intercondylar notch simplifies the examination compared to using the trochlear groove alone. A feasibility study conducted for this paper indicates that this second guideline value is an adequate replacement for the conventional measurement of the TT-TG. Especially in case of trochlea dysplasia the detection and definition of the groove may be difficult and the TT-IN value offers a reasonable alternative. Our study shows that the proposed sonography system is able to accurately determine the TT-TG in a population of symptom-free young subjects. These measurements range from  $13.1 \pm 4.2$  mm for male to  $14.8 \pm 3.4$  mm for female subjects. Our findings correspond to the postulated values of the gold standard. We are able to show that the values for the TT-IN are in a comparable range with  $14.4 \pm 4.1$  mm for men and  $13.6 \pm 4.0$  mm for women. We are convinced that this study strongly indicates that the TT-IN is a useful value that is easy to measure with a mobile ultrasound-based measurement*

system and can provide the same level of diagnostic value compared to the gold standard TT-TG. In conclusion, a new guideline value is presented to complement the measurement of the TT-TG when a pathological anatomy prevents the detection of the groove.

## INTRODUCTION

The mediolateral distance of the tibial tuberosity and the trochlear groove (TT-TG) is considered as the gold standard for patellofemoral pain syndrome (PFPS) or patella instability to determine the lateral shift of tibia and femur [1]. Goutallier et al. [2] described the TT-TG for the first time in radiological images. In 1994, a study by Déjour et al. [3] has shown a normal TT-TG range of  $12.7 \pm 3.4$  mm using superimposed computer tomographic slice images. More than 20 mm are considered as pathological. The image data of the tibial tuberosity (TT) and the trochlear groove (TG) are captured and superimposed in a transverse plane (Fig. 1) [4]. For the calculation, two auxiliary lines are constructed which are perpendicular to the tangent of the posterior femur condyles (Fig. 1, line A).

While one line starts at the lowest point of the trochlea (Fig. 1, line B), the other one runs through the tibial tuberosity (Fig. 1, line C). The distance between the parallel lines describes the TT-TG.

Apart from the radiation exposure in X-rays and the expenditure of time for MRI, both procedures are expensive and elaborate. In this paper we propose a novel measuring system based on navigated ultrasound which allows to detect bony landmarks and set them in relation. The implementation of a combined measuring and imaging method opens up innovative possibilities: First, a new way is presented to capture the TT-TG which the physician is familiar with. Secondly, a new parameter is defined as a reliable alternative for the TT-TG to which the physician can switch when a pathological anatomy prevents the detection of the trochlear groove. The measuring method and the defined parameters are evaluated in a study on symptom-free young subjects. Additionally, it is investigated if a sex-related difference of the TT-TG and the TT-IN is measured. This is motivated due to a 2:1 (female to male) incidence of PFPS [5].

## MATERIALS AND METHODS

Figure 2 represents the system components for the data acquisition and processing. The system includes

- 1 Microsoft Surface Pro 4 (Microsoft Inc., USA)
- 2 Ultrasound device Echo Blaster 128 (Teleded, Lithuania)

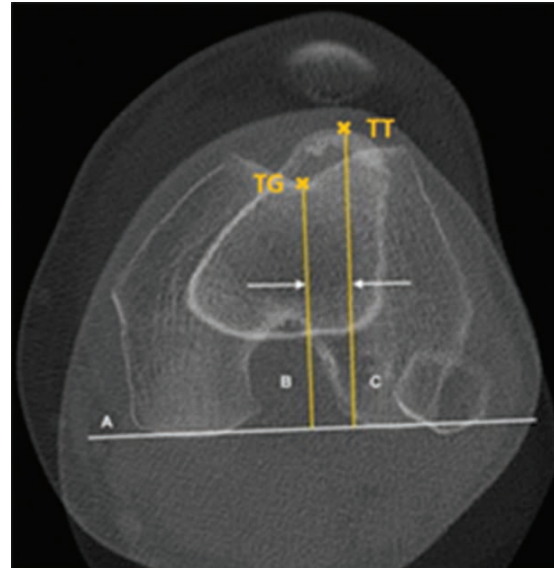


Figure 1. Superimposition of the computer tomographic slice images for calculation of the TT-TG (A: tangent of posterior femur condyles, B: line through lowest point of the trochlea (TG) perpendicular to line A, C: line through TT perpendicular to line A)



Figure 2. Components of the measuring system (1: Tablet Microsoft Surface Pro 4, 2: Ultrasound device, 3: iPhone 7, 4: Ultrasound probe and adapter with a marker, 5: Marker on a tape)

- 3 iPhone 7 (Apple Inc., USA)
- 4 Ultrasound probe (Teleded, Lithuania) and adapter with a marker (Aesculap AG, Germany)
- 5 Marker on a tape as reference coordinate system (Aesculap AG, Germany)

For the data transfer, the ultrasound device and the tablet are connected with a USB cable, the tablet and the smartphone communicate wireless via Wi-Fi Direct. The images are visualized and processed by the Microsoft Surface Pro 4. The technology is based on an ultrasound-based mobile tracking unit, which is able to capture the anatomical parameters.

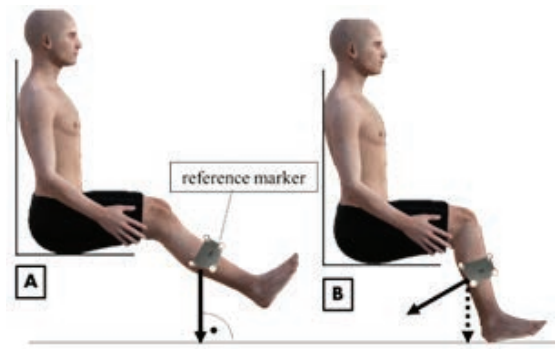
### TRACKING

Daniol et al. [6] describe the functionality of the used smart mobile tracking unit. The smartphone detects two markers, each of which is equipped with four passive retro-reflective spheres which reflect the flash light sent by the smartphone. Using image processing techniques and a 3D reconstruction algorithm the system computes the exact spatial position and orientation of these passive markers which are attached to the ultrasound probe and to a fixed reference frame. In this case the reference is attached to the tibia with a tape. Its function is to define a reference coordinate system where the landmarks are put into relation. The geometry of the markers and the arrangement of the spheres are unique and clearly distinguishable from each other for the localizing algorithm running on the smartphone [7]. The position and rotation data of the ultrasound probe are transferred to the tablet.

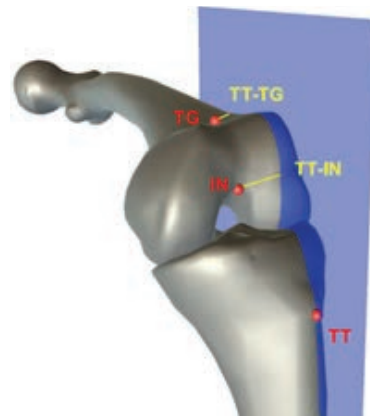### MEASURING PROCEDURE

For measuring the TT-TG and the TT-IN the anatomical landmarks need to be captured. Therefore, the acquired ultrasound images are automatically transferred to the screen of the tablet. From there the physician is able to manually mark the landmarks using a crosshair. To measure their lateral difference, a projection plane is needed. This plane is built perpendicular to the ground based on two gravity vectors. These vectors are built by the integrated orientation sensor of the mobile tracking unit and transferred into the reference coordinate frame of the marker. By using gravity, the vectors are independent of individual bone structures. They are captured by a change of the leg orientation before the landmarks re-cording.

To capture the gravity vectors the leg is lifted in a seated position whereby the movement originates from the knee joint until an extension angle of up to 20 degrees is reached (Fig. 3, position A). The first recording is performed and a gravity vector to the reference (Fig. 3, arrow) is generated. The leg is subsequently put down in approximately 60 degrees of knee flexion for the remaining measurement (Fig. 3, position B). A marking on the floor prevents an undesired leg rotation and ensures the defined knee flexion.



*Figure 3. Position A - Leg is lifted until extension up to 20 degrees for the generation of a gravity vector (arrow) to the reference marker, position B - Leg is put down in 60 degrees of knee flexion for a second gravity vector (dotted arrow) originating from the reference marker to build the projection plane perpendicular to the ground and based on these two gravity vectors*



*Figure 4. Graphic representation of the TT-TG and the TT-IN (landmarks are brought into relation to the projection plane)*

In this position the system generates another gravity vector originating from the reference marker (Fig. 3, dotted arrow). The gravity vectors span a projection plane. Next, the coordinates of the trochlear groove, the intercondylar notch and the tibial tuberosity are detected. The projection plane is translated to the landmark of the tibial tuberosity (Fig. 4).

For the detection of the landmarks the probe is first placed transversely above the patella (Fig. 5, right) and tilted from caudal to cranial until the depth of the landmark reaches its maximum. The deepest point of the echogenic structure is the trochlear groove (Fig. 5, left). The low point of this femoral landmark is marked by setting a crosshair on the captured ultrasound image.

A vector orthogonal to the projection plane (normal vector) originating from the trochlear groove or rather from the intercondylar notch (IN) is built. Thus the femoral landmark (IN or TG) is set in relation to the plane (ergo to TT) to measure their

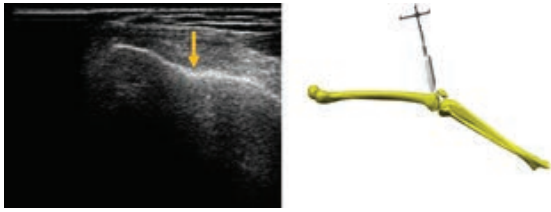


Figure 5. Ultrasound image of trochlear groove (left) and transverse posi-tioning of the ultrasound probe above the patella (right)

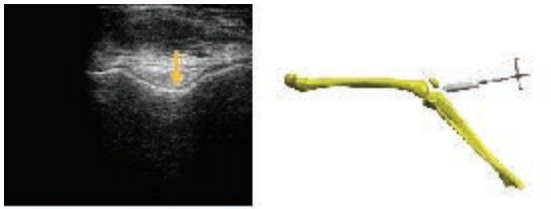


Figure 6. Ultrasound image of intercondylar notch (left) and transverse positioning of the ultrasound probe under the patella (right)

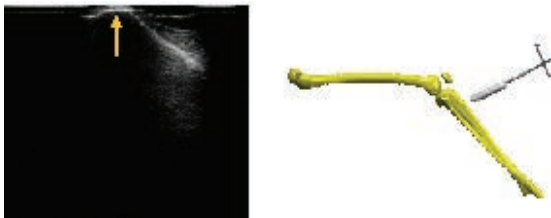

Figure 7. Ultrasound image of tibial tuberosity (left) and transverse posi-tioning of the ultrasound probe at the proximal tibia (right)

mediolateral distance as the normal vector length originating from the plane to the landmark. In this way the lateral distances from the trochlear groove to the tibial tuberosity (TT-TG) and from the intercondylar notch to the tibial tuberosity (TT-IN) are captured.

**STUDY ON SYMPTOM-FREE SUBJECTS**

The system is tested on 20 young subjects, half of them are female. A pathological background affecting the ana-tomical structure of the knee is excluded. The average BMI is 23.7 for men and 22.1 for women. The mean age is 30.3 years for men and 27.5 years for women.

A normal range of the TT-TG and the TT-IN is to be de-fined based on the study of these symptom-free young subjects. The examination is executed five times per sub-ject on the right knee. Subsequently, the average and standard deviation are calculated. The goal is to investi-gate whether the TT-TG values

Table 1. Average and standard deviation of the distances differentiated by gender

	TT-TG [mm]	TT-IN [mm]
male	13.1 ± 4.2	14.4 ± 4.1
female	14.8 ± 3.4	13.6 ± 4.0

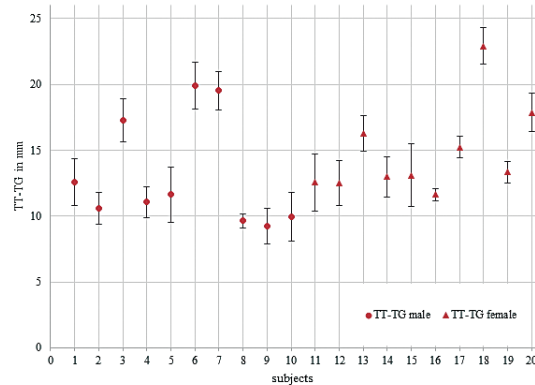


Figure 8. TT-TG of 20 symptom-free young subjects

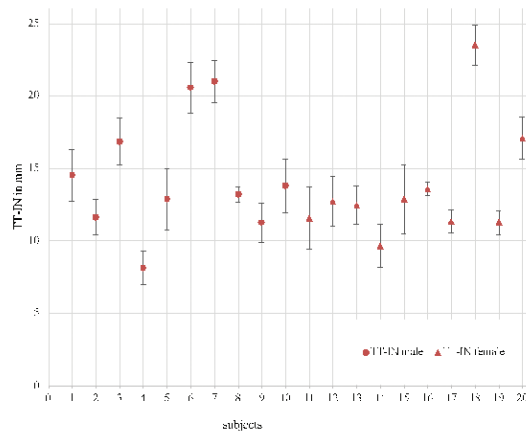


Figure 9. TT-IN of 20 symptom-free young subjects

differ from the gold standard and from the guide-line values published by Dé-jour et al. [3]. We also investigate whether the related TT-IN values offer a reasonable alternative which have the potential to complement the TT-TG values. Especially in case of trochlea dysplasia the detection and definition of the trochlear groove is difficult. Therefore, the position of the intercondylar notch contains a valuable information.

## RESULTS

In our study we have calculated the following values for the TT-TG and the TT-IN (Tab. 1). The mean values are presented as a function of sex. Positive values of the TT-TG and the TT-IN say that the tibial tuberosity is lateral to the femoral landmark. The normal range of the TT-TG corresponds to the postulated values of the gold standard.

A statistical analysis (U-Test) was performed with the hypothesis that the TT-TG shows no significant difference between males and females. The statement was confirmed, so the results of the test groups do not show sex-specific differences ( $p = 0.11$ ). The same applies to the TT-IN ( $p = 0.45$ ). The diagrams show the values for the TT-TG (Fig. 8) and for the TT-IN (Fig. 9).

Subsequently, we tested whether the hypothesis that these distances differ can be rejected. The range of the TT-TG is comparable with the TT-IN ( $p_{male} = 0.27$ ,  $p_{female} = 0.16$ ).

## DISCUSSION

The study on symptom-free young subjects shows promising results because the values for the TT-TG are comparable with the results of Déjour et al. [3]. For the TT-TG, values in the range of  $13.1 \pm 4.2$  mm for men and  $14.8 \pm 3.4$  mm for women are measured. The values for the TT-IN are in a comparable range with  $14.4 \pm 4.1$  mm for men and  $13.6 \pm 4.0$  mm for women. Therefore the TT-IN is a reliable alternative for the TT-TG to which the physician can switch when dysplasia prevents the detection of the trochlear groove. In both cases, a sex-specific difference is not noticeable. By utilizing gravity vectors to build a projection plane as a reference the measurement achieves a low error rate. However, the test group needs to be extended to conduct further examinations and confirm the results.

The measuring system based on navigated ultrasound is simple, mobile and cost-effective. In comparison to other technologies like X-rays, MRI or CT, the patient is not exposed to radiation and claustrophobia.

## CONCLUSION

In this study we verified and measured the normal range of the TT-TG and the TT-IN values based on 20 symptom-free young subjects. We have shown that the TT-TG values are similar to the range of the gold standard by Déjour et al. [3]. Furthermore, our results indicate that the TT-IN values of symptom-free young subjects do not differ significantly from their TT-TG values. The structure of the intercondylar notch is easy to detect due to its distinctive deepest point. It is a reliable landmark whose shape is not influenced in case of patellofemoral pain syndrome. Its importance is noticeable especially when the detection of the trochlear groove is prevented. Trochlea dysplasia (e.g. flat geometry) is not rarely a reason for PFPS or patella instability. The TT-IN is presented as a new alternative approach to evaluate patellofemoral pathology, i.g. pain or instability.

A major technical advantage is that smart navigated ultrasound provides imaging and measuring method in one. The smartphone-based sonographic measuring system has the potential to replace tomographic imaging. The presented method offers digital values and is free of radiation wherefore it is also applicable when no pathological indication is given.

## REFERENCES

- [1] S. Ostermeier and C. Becher, "Einfluss des Tubero-situstransfers auf das patellofemorale Gelenk," (de), *Arthroscopie*, vol. 23, no. 3, pp. 208–214, 2010
- [2] D. Goutallier, J. Bernageau, and B. Lecudonnet, "Mesure de l'écart tubérosité tibiale antérieure - gorge de la trochlée (T.A.-G.T.). Technique. Résultats. Intérêt," *Revue de chirurgie orthopédique et réparatrice de l'appareil moteur*, vol. 64, no. 5, pp. 423–428, 1978
- [3] H. Déjour, G. Walch, L. Nove-Josserand, and C. Guier, "Factors of patellar instability: an anatomic radiographic study," (eng), *Knee surgery, sports traumatology, arthroscopy: official journal of the ESSKA*, vol. 2, no. 1, pp. 19–26, 1994
- [4] S. Waldt and E. J. Rummeny, "Bildgebung der patellofemorale Instabilität," *Der Radiologe*, vol. 52, no. 11, pp. 1003–1011, 2012
- [5] D. Wagner, "Patellofemorales Schmerzsyndrom," Deutscher Ärzteverlag 6, 2017
- [6] M. Daniol, T. Martin, and J. Kozak, "Development, calibration, validation and comparison of mobile medical localizers based on smartphones Apple iPhone 5S and Samsung Galaxy S4," *Przeegląd Elektrotechniczny*, vol. 91, no. 5, pp. 53–56, 2015
- [7] T. Martin, J. Bassef-Neef, A. Alk, F. Derma, and J. Kozak, "A smart device based measuring system for pelvic tilt computation in hip arthroplasty," *Przeegląd Elektrotechniczny*, vol. R. 92, nr 3, 2016