

Received: 18.04.2020
Accepted: 01.10.2020A – Study Design
B – Data Collection
C – Statistical Analysis
D – Data Interpretation
E – Manuscript Preparation
F – Literature Search
G – Funds Collection

DOI: 10.5604/01.3001.0014.4549

HEALTH-RELATED QUALITY OF LIFE IN A PATIENT FOLLOWING ANEURYSMOTOMY OF RARE MEGA-GIANT ANEURYSM OF THE COMMON CAROTID ARTERY

Maria Paçhalska^{1(A,B,C,D,E,F)}, Mariusz Trystuła^{2(A,B,C,D,E,F)}¹ Chair of Neuropsychology and Neurorehabilitation, The Andrzej Frycz-Modrzewski Kraków Academy, Kraków, Poland² Department of Vascular Surgery and Endovascular Interventions, John Paul II Hospital, Kraków, Poland**Background:**

In the subject literature there are only a few articles devoted to the Health-Related Quality of Life (HRQoL) of patients with large extracranial aneurysms of the carotid artery segment. There are no reports on the quality of life of patients with rare Mega-Giant Carotid Artery Aneurysms (MGCAA) manifesting themselves as chronically large and growing neck tumors. The aim of the research was an evaluation of the health related quality of life (HRQL) of a patient following aneurysmotomy of Mega-Giant Carotid Artery Aneurysms (MGCAA).

Case study:

An 82-year-old patient was referred to the Department of Vascular Surgery at the John Paul II Hospital in Krakow, due to the presence of a mega-giant, painful tumor covering the entire left side of the neck. A physical examination and angio-CT confirmed the presence of a pulsating tumor, which extended vertically from the level of the angle of the mandible to the clavicle, and horizontally from the trachea to the cervical spine. An aneurysmotomy and reconstruction of LICA with cerebral protection using a shunt catheter was performed. The patient was awakened from anesthesia and extubated shortly after the procedure, without any Central Nervous System neurological defects. The surgery was complicated by left recurrent laryngeal nerve paresis and aphonia without dyspnoea, which was only partially resolved around 3 months after the operation itself. The postoperative period was uncomplicated. Health related Quality of Life (HRQoL) was studied using the 36-Item Short Form Health Survey (SF-36) to study both the clinical symptoms and how these symptoms would be reduced in a year follow up after the aneurysmotomy.

Conclusions:

Despite the increasing availability of endovascular options and techniques, open surgical repair of ICA aneurysms, especially Mega-Giant Carotid Artery Aneurysms (MGCAA), using cerebral protection (shunts), remains a basic option, providing an opportunity to avoid major intraoperative and postoperative complications. The aneurysmotomy, despite laryngeal nerve paresis and aphonia without dyspnoea, improves the patient's health-related quality of life.

Key words: Carotid arteries, Aneurysm, Surgical procedures

SUMMARY

INTRODUCTION

In the subject literature there are only a few articles devoted to the Health-Related Quality of Life (HRQoL) of patients with large extracranial aneurysms of the carotid artery segment. There are no reports on the quality of life of patients with rare mega-giant aneurysms manifesting themselves as chronically large and growing neck tumors, especially if the development of an aneurysm is perennial and the patient is fully aware of the risk of its rupture and impending death. Although mega-giant Extracranial Carotid Artery Aneurysms (ECCA) are extremely rare, they can cause severe clinical symptoms due to complications, and account for less than 1% of all peripheral artery aneurysms [Altun et al. 2018].

Aneurysms can be classified as real and pseudoaneurysm. According to meta-analysis reports, most carotid aneurysms are pseudoaneurysm [Longo and Kibbe 2005; Ni et al. 2016]. This type of aneurysm is associated with the interruption of continuity within some layers of the artery wall and the formation of a vibrant, expanding hematoma, which is associated with the formation of a painful tumor [Faggioli et al. 2015]. Most often, pseudoaneurysms arise following an injury to the arteries, less often so after operations such as endarterectomy of the internal carotid artery (ICA). They can also arise as a result of the emergence of atherosclerotic plaque ulcers, weakening the wall of the vessel and its subsequent rupture.

Real aneurysms are the result of stretching the all layers of the artery walls [Longo and Kibbe 2005; Cinar et al. 2006]. They represent less than 10% of ECCA [Altun et al. 2018]. Some cases can be asymptomatic. The most common local symptoms are: the presence of a pulsating tumor, often painful in the tumor area. The most common cause of the development of a real aneurysm is an atherosclerotic lesion of the arterial wall.

A rarer etiological cause is genetically determined structure disorders or collagen damage such as fibromuscular dysplasia, Marfan syndrome, Ehlers–Danlos syndrome, osteogenesis imperfecta, and pseudoxanthoma elasticum, Behcet's disease, Takayasu's arteritis, or Cogan's syndrome, prior radiotherapy in the neck area, surgical trauma and infection (Tuberculosis, Human Immunodeficiency virus, Salmonella infection, Syphilis, fungal infection) [Royce & Steinmann 1993; Papadoulas S, Zampakis P, Liamis et al. 2007; Singh AA, Velineni R, Varty et al. 2019; Cinar et al. 2006; Attigah et al. 2009]. These can be life-threatening if they rupture or embolise the cerebral vessels causing an ischemic stroke [DeFatta et al 2005; Cinar et al. 2006; Attigah et al. 2009; Faggioli et al. 2015].

There are five different types of ECCA aneurysms as defined by Attigah et al. (2009), based on the extracranial localisation of the aneurysm:

- Type I – Isolated aneurysms of the ICA
- Type II – Aneurysms of the complete ICA with involvement of the bifurcation
- Type III – Aneurysms of the carotid bifurcation
- Type IV – Combined aneurysm of the internal and CCA
- Type V – Isolated aneurysm of the CCA.

Giant aneurysms are dangerous. The mortality rates for untreated Giant Carotid Artery Aneurysms (GCAA) have been reported to be as high as 65 and 100% after 2–5 years of follow-up [Kodama, Suzuki 1982; Peerless, Wallace, Drake 1990], with a rupture rate for conservatively treated intradural giant aneurysms of roughly 8–10% per year [Wiebers, Whisnant, Huston et al. 2003]. Morphologically, giant aneurysms are divided into saccular and fusiform types, with fusiform aneurysms arising more commonly intracranially, in the vertebra basilar and middle cerebral territories [Barrow, Alleyne 1995]. The treatment of smaller GCAs, is generally directed toward complete exclusion of the lesion from the circulation, with the preservation of flow in the damaged artery. Garg, Rockman, Lee et al. (2012) have pointed out surgical management options of the ECCA: aneurysm clipping, excision with primary anastomosis, excision with a graft interposition, extracranial/intracranial bypass, and carotid ligation.

The methods of carotid artery aneurysm treatments are changing, connected with the increasing availability of endovascular options and techniques including bare-metal stent placement with or without trans-stent coil embolization of the aneurysm sac, exclusion of the aneurysm using a stent graft, or endovascular occlusion of the carotid artery (Selverstone clamping with delayed proximal occlusion).

From the technical point of view, endovascular repair of these lesions is often not favorable because of the frequently broad necks, distorting the anatomy of the parent vessel, outgoing branch arteries at the base or even from ICA, and a fairly high incidence of intraluminal thrombosis causing brain embolisation. These anatomic factors make giant aneurysms difficult to coil and obliterate completely, leading to residual or recurrent aneurysms, multiple re-treatments, occasional re-hemorrhages, and neurological deterioration from progressive aneurysm enlargement.

Current endovascular techniques (coil embolization with or without balloon assistance, neck remodeling with stents, liquid embolics, etc.) for the treatment of giant cerebral aneurysms still carry significant periprocedural risks for the patients. These risks are only compounded by the severity of their cerebral vascular pathology, and many times are not satisfactory in terms of the long-term durability of aneurysm occlusion. Flow diverting stents implanted into extracranial aneurysm have provided many promising early results [Kim, Park, Lee et al. 2019].

The reported modern surgical mortality rates for the treatment of both ruptured and unruptured giant aneurysms vary between 6% and 22% [Lawton & Spetzler 1995; Gewirtz & Awad 1996]. A few authors have noted that this was not a major complication (death) but a high index of cranial nerves injury [Zhou, Lin, Bush, et al. 2006; Ni, Pu, Zeng et al. 2016; Sriamornrattanukul, Sakarunchai, Yamashiro et al. 2017].

In any case, both true aneurysms and pseudoaneurysms are associated with the risk of the above complications, so they are related to the quality of life. The situation of the patient can be aggravated by the fact that he/she is aware of:

- On the one hand – the risks associated with the occurrence of pathology, as well as the occurrence of complications in the situation if there is no possibility of treating this pathology,

- On the other hand, uncertainty about whether a medical center will undertake treatment, and even if so, there are concerns about the risk of significant or minor intraoperative complications.

Aneurysmotomy of Mega-Giant Carotid Artery Aneurysms (MGCAA) is fraught with a high risk of failure, so very few centers undertake the treatment only. This is due to, among other things, the lack of guidance on how to treat such an aneurysm itself [Sriamornrattanakul et al 2017], than the proposal of any psychological support for such a patient.

In this article, we present the Case Study of a patient with a real, long-standing Mega-Giant Carotid Artery Aneurysms (MGCAA) that had ruptured with the formation of an additional mega-giant pseudoaneurysm. The purpose of this study is to provide an anatomical analysis of the aneurysm, a description of the diagnosis and the decision-making approach, surgical procedure, and the quality of life of the patient before the operation and in follow up a year later.

CASE STUDY

A 82-year-old patient was urgently transferred from the General Surgery Department to the Department of Vascular Surgery at the John Paul II Hospital in Krakow, due to the presence of a mega-giant, painful tumor covering the entire left side of the neck (Fig. 1).

In the clinical history, it was reported that the patient had, 30 years earlier, had a tumor, about 2 cm in diameter, on the left side of the neck, accompanied by pain radiating to the throat. The patient denied the occurrence of injury or inflammation. This tumor slowly grew and ceased to be painful. After 12 years, the tumor significantly enlarged and the pain problems reappeared. The patient was referred for ultrasound, during which the diagnosis of an ICA aneurysm was first made. The patient was offered surgery with information about the high risk of complications (stroke). As a result, the patient did not agree to the operation, motivating her decision by the need to raise single-handedly three young children. After 29 years

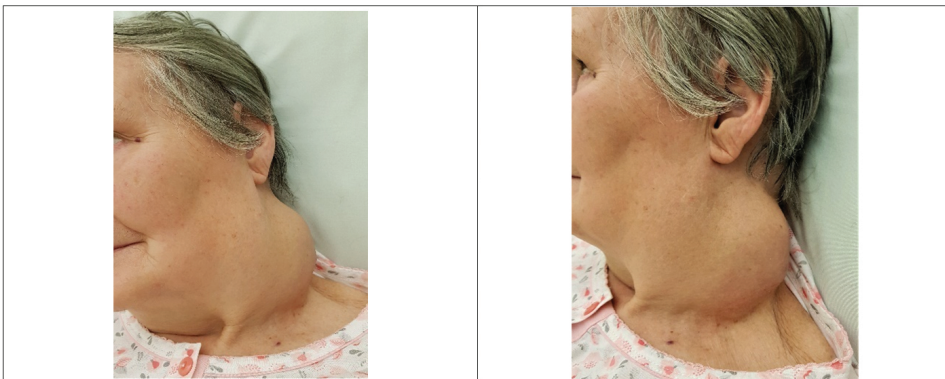

Fig. 1. Image of a mega-giant tumor covering the entire left side of the neck. Visible forced head arrangement with rotation and tilt to the right

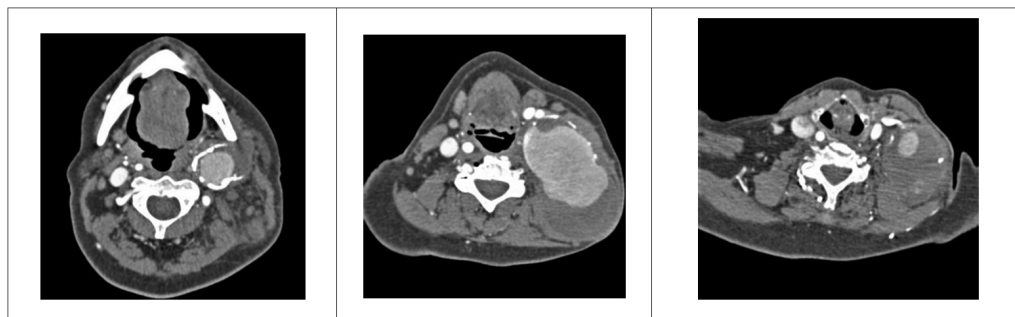


Fig. 2. Aneurysm image in angio-CT scans; 1). At the level of the C2/C3vertebral body; 2). At the level of the C5 vertebral body, 3). At the level of the C7 vertebral body.

Source: Angio-CT examination, John Paul II Hospital, Kraków

from its inception, the tumor had grown rapidly, expanded and caused significant pain with reduced head mobility. One year after this event, when a re-acceleration of tumor growth was noticed (about 3 weeks before admission to hospital), the patient decided to re-see her GP doctor and seek treatment.

A physical examination and angio-CT confirmed the presence of a pulsating tumor, which extended vertically from the level of the angle of the mandible to the clavicle, and horizontally from the trachea to the cervical spine. The tumor caused the patient's head to be forcibly tilted to the right with a large restriction in the torsional movement of the head.

An angio-CT study confirmed a mega-giant aneurysm 11.5x9.5x7 mm which was formed 5 cm above the division of the left common carotid artery (LCCA) with almost a half of its volume being a real aneurysm, with a visible wall calcification. The primary aneurysm pouch of about 57x55x47 mm expanded backwards and formed an additional pseudoaneurysm, whose wall, in contrast, had no calcifications.

In the tomography images, about 30-40% of the volume of the aneurysm bag was attached to the wall thrombus. The entrance to the aneurysm sac was about 5 cm from the division of the left common carotid artery (LCCA).

Surgical treatment

It was decided to undertake surgical treatment as being deemed more safe to open the aneurysm after the proximal and distal LICA preparation, establishing protection with the use of a shunt catheter and undertaking any further decision depending on the intraoperative presentation. The procedure was carried out under general anesthesia with endotracheal intubation. The incision in was carried out at the site of the highest tumor elevation, along the laterally extended anterior edge of the sternocleidomastoid muscle. Due to the significant degree of compression and displacement of tissues by the aneurysm, it was only possible to prepare the left common carotid artery (LCCA) and the proximal segment of LICA. The left outer part of the carotid artery (LECA) could not be separated.

The distal section of LICA (departing from the aneurysm bag) was located high behind the angle of the mandible, without the possibility of its visualization. It was decided to make an incision in the aneurysm and to place the shunt proximally to the prepared section of LICA, and to the distal section of LICA, whose entrance was in the aneurysm bag, under visual control. After successfully carrying out this part of the procedure, it was possible to mobilize both: laying 5 cm apart the LICA ends, so that they could be joined “end-to-end” with a 6-0 Prolenesuture and removing the shunt before the sewing was finished.

After finishing both ends of the LICA anastomosis, the residual blood and thrombus were evacuated from the aneurysm sac and much of the old, calcified wall of the aneurysm was removed as well. Redon’s drainage from a separate skin incision was indwelled into the wound. Hemostasis was performed. The wound was stitched in layers, following the excision of the edges of the wound for good cosmetic effect. The patient was awakened from anesthesia and extubated shortly after the procedure, without Central Nervous System neurological defects.

The surgery was complicated by left recurrent laryngeal nerve paresis and aphonia without dyspnoea, which was partially resolved about 3 months following the operation. The postoperative period was uncomplicated. Redon’s drainage was removed in the 3rd day after surgery. In the 1st day after the procedure, it was not necessary to continue with the anxiolytic drugs used from the 2nd day prior to surgery. NSAIDs were used for 4 days following surgery.

The patient was discharged from hospital on the 5th day after the operation. During the follow-up visit after 3, 7, 14 and 30 days and after the subsequent 6 months and 12 months, the patient did not report any additional ailments and the wound healed perfectly (Fig. 4).

Image of the angio-CT LICA examination 6 months after surgery is presented in fig. 5. The left part of the calcified wall of the aneurysm is visible.

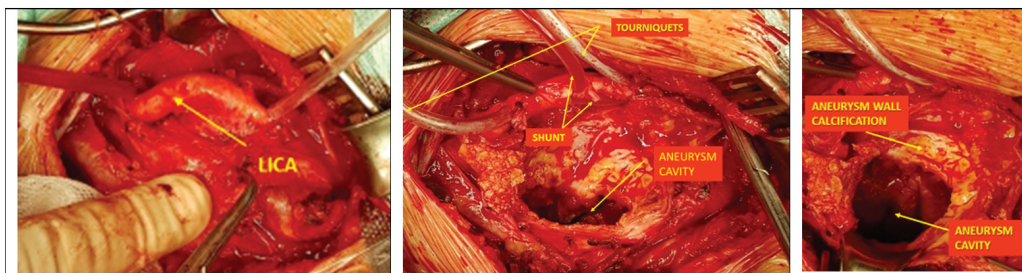


Fig. 3. Operating field:

- 1) During the preparation of the proximal section of LICA;
- 2) After shunt indwelling into the proximal and distal art of LICA (the distal entrance to LICA is invisible);
- 3) Aneurysm cavity. Visible old calcifications of the primary real aneurysm (bright wall tissues), and in the depths – the wall of the purported aneurysm (no calcification).

Source: photo M. Trystula

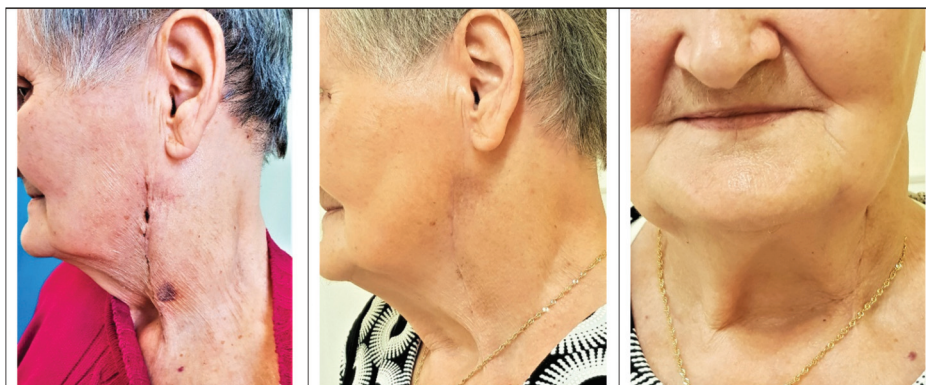

Fig. 4. Scar on the neck after surgery: from the left – 14 days; in the middle and to the right – 6 months after surgery
Source: photo M. Trystuła

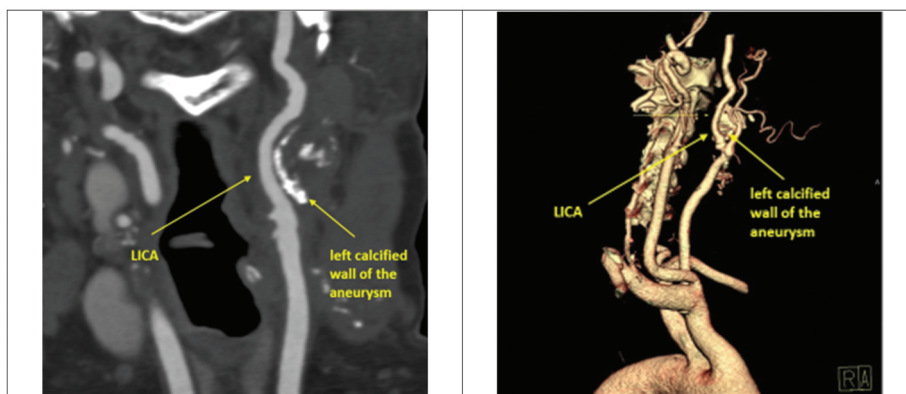


Fig. 5. Image of the angio-CT LICA examination 6 months after surgery. Source: clinical material of M. Trystuła
Source: Angio-CT examination, John Paul II Hospital, Kraków

Bacteriological examination of the samples taken of the aneurysm wall allowed one to exclude inflammatory (infectious) etiology and adopt atherosclerotic etiology of its formation.

The patient was operated on in a new operating theater with a hybrid room at the John Paul II Hospital in Kraków, **equipped with modern endovascular technology** (see: Fig. 6).

It is worth noting that before the procedure the patient, being fully aware of the risks, manifested a huge fear of operational complications. In addition, she had several sessions with a clinical psychologist. It was also necessary to include drugs from the anxiolytic group. After the procedure, she manifested an elevated mood, and reported the disappearance of the neck swallowing pain, associated with the presence of compression on the part of the aneurysm, and she was

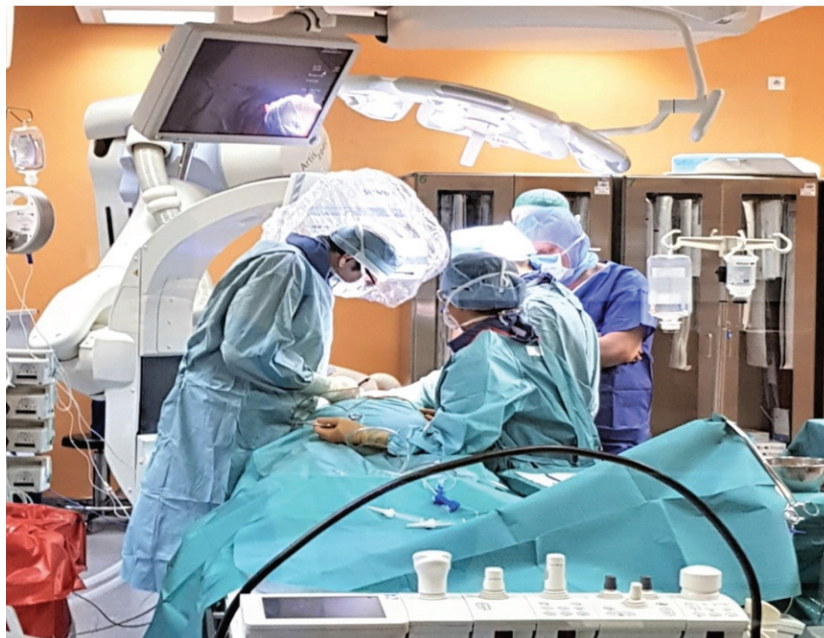

Fig. 6. New operating hall with hybrid room at the John Paul II Hospital in Cracow
Source: photo M. Trystula

pleased that the pain from the surgical wound was significantly less than the pain she had felt before the procedure. She did not complain much about the complication in the form of aphonia.

The protocol of the experiment

Used was the standard protocol as employed in the Department of Vascular Surgery at the John Paul II Hospital for qualification for the proper method of revascularisation, and here by a panel of experts (the vascular team), as equally for the testing of all patients treated in our department, (Fig. 7). Accordingly, our patient was tested four times: before the operation, after 2-3 days, three months and 12 months following the operation.

The evaluation of HRQoL was carried out with the use of the Medical Outcomes Study Questionnaire Short Form 36 Health Survey (SF-36) [Ware & Sherbourne, 1992]. This scale consists of a 36-item, patient-reported survey of the patient's health, and their measure of health status. The results might be evaluated in eight scaled scores, which are the weighted sums of the questions in their section. Each scale is directly transformed into a 0-100 points and the value of the score is indirectly proportional to the number of complaints. This means that better quality of life is reflected by a higher score, and the fewer complaints and limitations, and worse quality of life is reflected by a lower score, and more complaints and limitations (Pąchalska, MacQueen, Moskała et al. 2014).

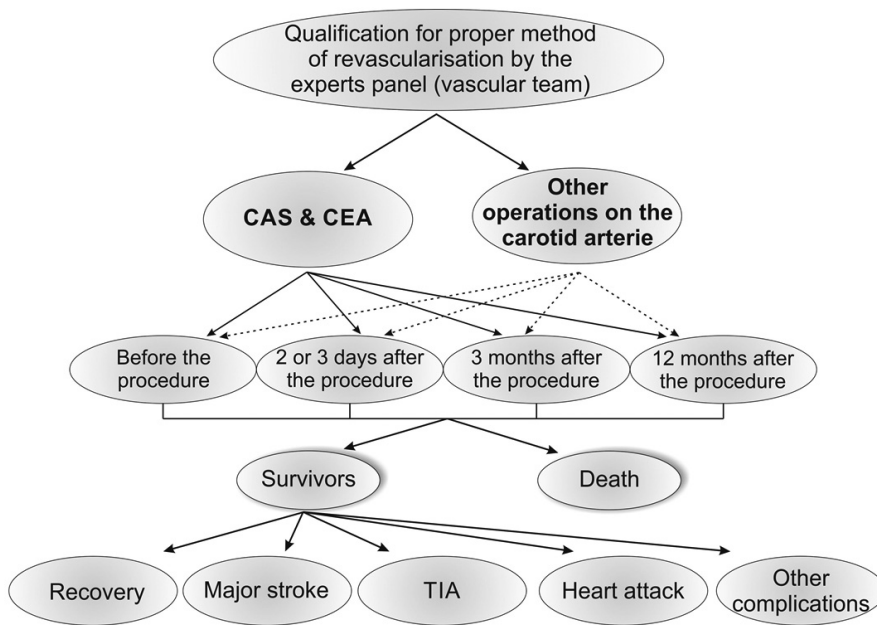


Fig. 7. The study protocol
Source: M. Pachalska's elaboration

Ethics statement

According to the guidelines of the Helsinki Declaration (2008), subjects participating in the experiment were informed in detail about the test procedure and they provided written consent for their participation in the project. The study protocols received ethical approval from the Ethical Committee of the Regional Medical Chamber (KB6/16).

RESULTS

The results obtained by the patient are presented in Fig. 8. It was found, that in the 1st examination (before the operation) the HRQoL level was low for all eight SF-36 scales. The patient complained that she was weak (scale: vitality), felt neck swallowing pain (scale: bodily pain), and an immense fear (scale: role emotional) of operational complications, while being fully aware of the risks.

Significant changes were observed in all of the SF-36 scales in the 2nd, 3rd and 4th examination, suggesting that responsiveness was dependent on the timing of follow-up. The patient manifested an elevated mood (scale: role emotional), reported the absence of neck swallowing pain (scale: bodily pain), and she stated that the pain of the surgical wound was significantly less than the pain she had felt before the procedure. Her positive attitude caused that complications in the form of aphonia were completely downplayed by her.

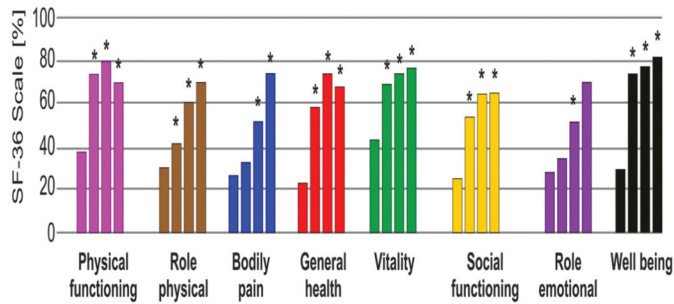


Fig. 8. SF-36 score in the 1st, 2nd, 3rd and 4th examination

DISCUSSION

The basic diagnostic tool in pathology of the carotid arteries is an ultrasound examination with color imaging (USG-Doppler, triplex scan), especially as it is inexpensive, easily available and does not expose the patient to ionizing radiation. However, the gold standard, especially in the presence of an ICA aneurysm, is digital subtraction angiography (Angio-CT). This allows for a detailed assessment of the vessel walls and extravascular structures, and thus appropriate planning of the surgical procedure. Magnetic resonance angiography (MRA) is also a useful diagnostic tool, which has the advantage of avoiding exposure to ionizing radiation and iodinated contrast. Sometimes we need to investigate the patient's cerebral circulation. This can be done by a MRA with enhancing accuracy [Hori, Okubo, Aoki et al. 2005]. Conventional angiography is an invasive option which, especially in the presence of an ICA aneurysm, gives less information than the above-mentioned.

Early risk of mortality in open surgical procedures ranges from 0 to 7%, perioperative stroke 0.7 to 11%, cranial nerve injury 0 to 66%, hematoma 0 to 5%, acute renal failure 0 to 1.5%, thrombosis 0 to 6%, myocardial infarction 0 to 1.7%, and infection 0 to 1.7% [Zhou W, Lin P H, Bush et al. 2006]. Cranial nerve injuries include facial, vagus, spinal accessory, hypoglossal, and glossopharyngeal nerves. To minimize the risk of embolization and dissection during aneurysm surgery, minimizing any manipulation of the aneurysm during procedure is recommended [Kraemer, Zhou et. al. 2019; Attigah, Külkens, Zausig et al. 2009; Pulli, Dorigo, Alessi et al. 2013].

After reconstructing CT angiography scans of the left internal carotid aneurysm (LICA) it was found that the proximal segment of the LICA is at an angle of approximately 50 degrees to the distal segment. The entrance of the aneurysm is about 5 cm above the LCCA division. This would make it very difficult during an endovascular procedure to find the outlet to the distal LICA section, to catheterize it, to place within it a distal brain protection device and to maintain all of this while implanting the stent or covered stent (arterial stent-graft). It might be also difficult to remove safely the brain protection device at the end of the procedure.

An additional risk was the possibility of clot release from the aneurysm sac during manipulation of the guide wire, and the inducing of embolism of the cerebral vessels as a result. In addition, leaving such a large amount of blood in the aneurysm sac out of stent-graft, would certainly not improve the quality of patient life with an ever-existing risk of leakage, not to mention the possibility of its infection. Consequently, even if the endovascular procedure went off without complications, it would still be necessary to remove surgically the blood tank and clots by an opening of the aneurysm.

Iflé et al. (2020) have presented the results of open repair of two ipsilateral extracranial ICA aneurysms. He stated that the procedure might be safe when using visualisation of the vascular anatomy and distance measurements for careful pre-operative planning. Sometimes, in order to maximise exposure you must divide the digastric muscle, conduct styloidectomy, if necessary, and carry out mandibular subluxation.

The most common complication of ECAA open surgery is damage to the cranial nerves, especially when they are displaced by a pressing tumor. In world subject literature, nerve injury occurs transiently in 11%–22% of cases and permanently in 3%–13% of patients [Attigah, Kulkens, Zausig, et al. 2009].

The operation procedure as well as the pre- and postoperative standards of care for a patient with mega-giant aneurysm of the common carotid artery as elaborated on and utilized at the Department of Vascular Surgery with Endovascular Procedures of the John Paul II Hospital, Krakow may be of use in conducting further research aimed at discovering the optimal effectiveness of this revascularization method for the patient physical and psychic functioning, especially emotional and cognitive control and therefore for the health-related quality of life (see also: Pączalska 2019). It also creates a possibility for the introduction of this procedure into other clinical centers.

CONCLUSIONS

Despite the increasing availability of endovascular options and techniques, open surgical repair of ICA aneurysms, especially mega-giant aneurysms, using cerebral protection (shunts), remains a basic option, giving a chance to avoid major intraoperative and postoperative complications. The aneurysmotomy, despite laryngeal nerve paresis and aphonia without dyspnoea, improves the patient's health-related quality of life.

REFERENCES

- Altun, G., Pulathan, Z., & Hemsinli, D. (2018). True Aneurysms of the Extracranial Carotid Artery: An Evaluation of Two "Giant Aneurysms" and the Current Literature. *Journal of Korean Neurosurgical Society*, 61(2), 282–286. doi:10.3340/jkns.2017.0404.003.
- Attigah, N., Kulkens, S., Zausig, N. et al. (2009). Surgical therapy of extracranial carotid artery aneurysms: long-term results over a 24-year period. *Eur J VascEndovasc Surg*, 37(02), 127–133.
- Barrow, DL., Alleyne C. (1995). Natural history of giant intracranial aneurysms and indications for intervention. *Clin Neurosurg* 42:214–244 2.

- Cinar, B., Fazlioğullari, O., Goksel, O. (2006). True aneurysm of extracranial internal carotid artery in a 10-year-old. *Eur J VascEndovasc Surg*, 32, 386–388.
- DeFatta, R.J., Verret, D.J., Bauer, P. (2005). Extracranial internal carotid artery pseudoaneurysm. *Int J PediatrOtorhinolaryngol*, 69, 1135–1139.
- Faggioli, G.L., Freyrie, A., Stella, A., Pedrini, L., Gargiulo, M., Tarantini, S., et al. (2015). Extracranial internal carotid artery aneurysms: Fankhauser, G.T., Stone, W.M., Fowl, R.J., O'Donnell, M.E., Bower, T.C., Meyer, F.B., et al. Surgical and medical management of extracranial carotid artery aneurysms. *J Vasc Surg*, 61, 389–393.
- Garg, K., Rockman, C.B., Lee, V., Maldonado, T.S., Jacobowitz, G.R., Adelman, M.A., et al. (2012). Presentation and management of carotid artery aneurysms and pseudoaneurysms. *J Vasc Surg*, 55, 1618–1622.
- Gewirtz, R.J., Awad, I.A. (1996). Giant aneurysms of the anterior circle of Willis: management outcome of open microsurgical treatment. *Surg Neurol*, 45, 409–421.
- Hori, M., Okubo, T., Aoki, S., Ishigame, K., Araki, T., Nukui, H. (2005). The magnetic resonance matas test: Feasibility and comparison with the conventional intraarterial balloon test occlusion with SPECT perfusion imaging. *J MagnReson Imaging*, 21,709–714.
- Iflé, I.G., van Lammeren, G.W., van Prooijen, W.E., de Smet, A. AEA (2020). Open Repair of Two Ipsilateral Extracranial Internal Carotid Artery Aneurysms. *EJVES Vasc Forum*, 48, 8–11. Published online 2020 Jun 11. doi: 10.1016/j.ejvsf.2020.06.001.
- Kim, B.M., Park, K.Y., Lee, J.W., Chung, J., Kim, D.J., Kim, D.I. (2019). A Newly-Developed Flow Divorter (FloWise) for Internal Carotid Artery Aneurysm: Results of a Pilot Clinical Study. *Korean J Radiol, Mar; 20(3)*, 505–512. Published online 2019 Jan 21. doi: 10.3348/kjr.2018.0421.
- Kodama, N., Suzuki, J. (1982). Surgical treatment of giant aneurysms. *Neurosurg Rev* 5:155–160.
- Kraemer, C.J.K., Zhou, W. (2019). Carotid Aneurysm Review, *Int J Angiol, Mar; 28(1)*, 17–19. Published online 2019 Feb 27. doi: 10.1055/s-0039-1677675.
- Lawton, M.T., Spetzler, R.F. (1995). Surgical management of giant intracranial aneurysms: experience with 171 patients. *Clin Neurosurg*, 42, 245–266.
- Longo, G.M., Kibbe, M.R. (2005). Aneurysms of the carotid artery. *Semin Vasc Surg*, 18, 178–183.
- Ni, L., Pu, Z., Zeng, R., Zhang, R., Zheng, Y.H., Ye, W., et al. (2016). Endovascular stenting for extracranial carotid artery aneurysms: experiences and mid-term results. *Medicine (Baltimore)*, 95, e5442.
- Papadoulas, S., Zampakis, P., Liamis, A., Dimopoulos, P.A., Tsolakis, I.A. (2007). Mycotic Aneurysm of the Internal Carotid Artery Presenting with Multiple Cerebral Septic Emboli, *Vascular*, 15(4), 215-220. <https://doi.org/10.2310/6670.2007.00043>.
- Pąchalska, M., MacQueen, B.D., Moskała, M., Tomaszewski, W. (2014). *Europejska Skala Oceny Jakości Życia Po Urazie Mózgu. Standaryzowana wersja polska*. Warszawa: Medsportpress.
- Pąchalska, M. (2019). Event-related potentials as an index of lost cognitive control and lost self in a TBI patient with duration increasing post-traumatic delusional misidentification syndrome concluded with Cotard syndrome. *Acta Neuropsychologica*, 17(4), 487-508. DOI: 10.5604/01.3001.0014.4268.
- Peerless, S.J., Wallace, M.C., Drake, C.G. (1990). Giant intracranial aneurysms. In: Youmans JR (ed.) *Neurological surgery: a comprehensive reference guide to diagnosis and management of neurological problems*. Saunders, Philadelphia, pp 1742–1763 10.
- Pulli, R., Dorigo, W., Alessi Innocenti, A., Pratesi, G., Fargion, A., Pratesi, C. (2013). A 20-year experience with surgical management of true and false internal carotid artery aneurysms. *Eur J VascEndovasc Surg*, 45(01), 1–6.
- Royce, P.M., Steinmann, B.U. (1993). *Connective Tissue and its Heritable Disorders: Molecular, Genetic, and Medical Aspects*. NewYork: Wiley-Liss.
- Singh, A.A., Velineni, R., Varty, K., Gohel, M.S. (2019). Bilateral Extracranial Internal Carotid Artery Aneurysms in a Patient with Marfan Syndrome: Case Report and Review of the Literature, *EJVES Short Rep*, 45, 14–16. Published online 2019 Sep 25. doi: 10.1016/j.ejvsr.2019.08.003.
- Sriamornrattanukul, K., Sakarunchai, I., Yamashiro, K., Yamada, Y., Suyama, D., Kawase, T., & Kato, Y. (2017). Surgical treatment of large and giant cavernous carotid aneurysms. *Asian journal of neurosurgery*, 12(3), 382–388. doi:10.4103/1793-5482.180930.

- Ware, J.,E., Sherbourne, C.,D., (1992), The MOS 36-Item Short-Form Health Survey (SF-36®): I. conceptual framework and item selection. *Med Care*; 30(6):473-83.
- Wiebers. D.O., Whisnant, J.P., Huston. J. 3rd, Meissne, I., Brown, R.D. Jr, Piepgras, D.G., Forbes, G.S., Thielen, K., Nichols, D., O'Fallon, W.M., Peacock, J., Jaeger, L., Kassell, N.F., Kongable-Beckman, G.L., Torner. J.C.; International Study of Unruptured Intracranial Aneurysms Investigators (2003). Unruptured intracranial aneurysms: natural history, clinical outcome and risks of surgical and endovascular treatment. *Lancet* 362:103–110.
- Zhou, W., Lin, P. H., Bush, R. L. et al. (2006). Carotid artery aneurysm: evolution of management over two decades. *J Vasc Surg*, 43(03), 493–496.

Address for correspondence:

Maria Pachalska

Chair of Neuropsychology and Neurorehabilitation

Andrzej Frycz Modrzewski Cracow University, Cracow, Poland

Herlinga-Grudzinskiego 1

30-705 Krakow

e-mail: neuropsychologia23@go2.pl